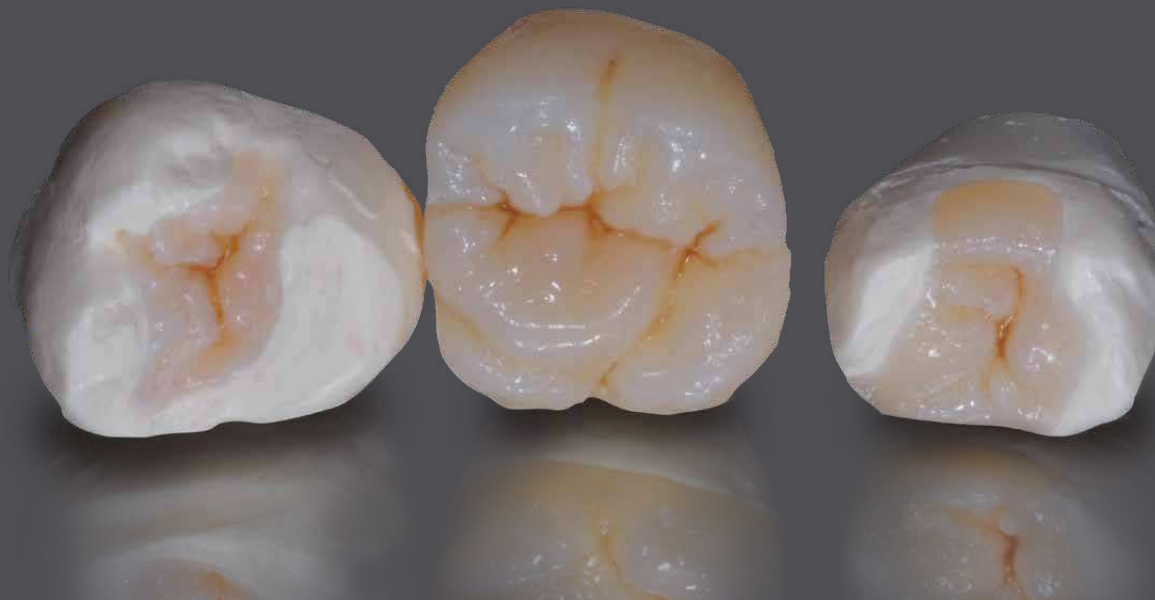

visio.lign crea.lign



inverse layering technique

- Non-prep technique
- Minimally invasive preparation
- Inlay, Onlay, Overlay
- Complex case

bredent^{group}

Properties crea.lign

crea.lign is a light-curing composite,

which consists of 50% opalescent ceramic particles and a high-strength oligomer matrix. crea.lign veneering material contains only nanofillers and does not have any ground glass fillers. A special manufacturing process eliminates any agglomerates or lumping and a homogeneous and dense surface is achieved with the particle size of 40 nm.

The omission of harder glass fillers which lead to embrittlement in composites results in excellent polishing properties and a high resistance to plaque and abrasion.

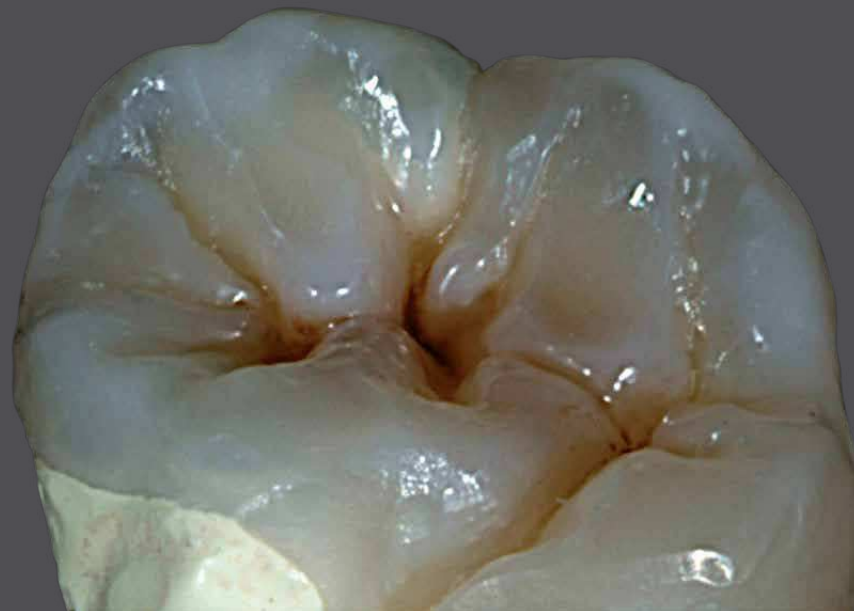The special gel-like consistency and homogeneity of the material allows for the adaption of elasticity and hardness of the composite to various substructure materials. The combination of opalescent ceramic and crack-resistant composite matrix transforms the properties of a liquid ceramic to crea.lign. Using a simple procedure, restorations perfectly matching natural teeth can be produced.

Accordingly, crea.lign can be used to easily produce long-term restorations with shade stability and plaque resistance in the laboratory. It can also be used chairside, which could previously only be achieved with veneering ceramic. crea.lign is not only suitable for crowns and bridges but also for the „additional veneer technique“, as described in this brochure.

visio.
crea.

Contents

Preface.....	4
inverse layering technique	5
Non-prep technique	6
Minimally invasive preparation	12
Inlay, Onlay, Overlay	20
Complex case	38
Vincenzo Musella	54



align

Preface

“Non-prep technique” and “minimally invasive preparation technique”

Preparation of the tooth has always been considered to be an essential precondition for the production of a prosthetic restoration. In the preparation process material is removed to create space for build ups or inserting dental restorations. The removal of natural tooth structure results in considerable loss of biological material. Loss of structure can be limited through the application use of adhesive bonding technique, which is used when luting/cementing veneers. In such cases, however, the preparation results in irreversible - yet limited - damage. In recent years a new type of prosthetic therapy has been endorsed, which enables esthetic and/or functional correction of the tooth through the use of very thin veneers. The veneers are luted directly to the etched enamel without using a substructure.

Numerous advantages can be observed:

- complete reversibility of the prosthetic treatment
- no destruction of hard tooth structure (biological loss) caused by preparation
- excellent adhesive bonding, directly to the enamel

The indication range includes cases in which the intended dimension of the tooth is larger than the existing dimension. Such „additional veneers“, are based on a complex procedure, which depends highly on the dental technician’s skills. Moreover it is possible to expand the indication range of these „additional veneers“ by preparing the tooth in a minimally invasive manner. If parts of a tooth to be restored represent a potential constraint to the use of an „additional veneer“, minimal preparation is suitable to change the shape of the tooth by slightly reducing the tooth structure without the need for full preparation of the tooth. In this case, minimal removal of tooth surface is also based on the concept of reversibility and the advantage of direct bonding to the enamel is maintained.

vision
created

inverse layering technique

“inverse layering technique”

Traditionally, composite restorations are produced using a direct additive technique.

This method has fundamentally changed through the use of “inverse layering technique” in which the restoration is produced by using a reverse approach - the so-called “inverse layering technique”.

The wax-up is of utmost significance when using this technique since a successful restoration depends on a carefully and precise wax work.

In the step-by-step description of this technique, a key made of transparent silicone (shore hardness: 60) is prepared after waxing up. This key needs to reproduce all details of the model in a very accurate manner.

Once the transparent key is completed, inverse layering is carried out; transparent materials and first dentine are applied followed by dentine materials with different levels of chroma.

When using this technique, it is important to keep in mind that the use of conventional, flowable composites poses certain risks due to their limited stability.

Therefore it is essential to select a suitable composite, which is less susceptible to fracture (brittle) and features high mechanical strength.

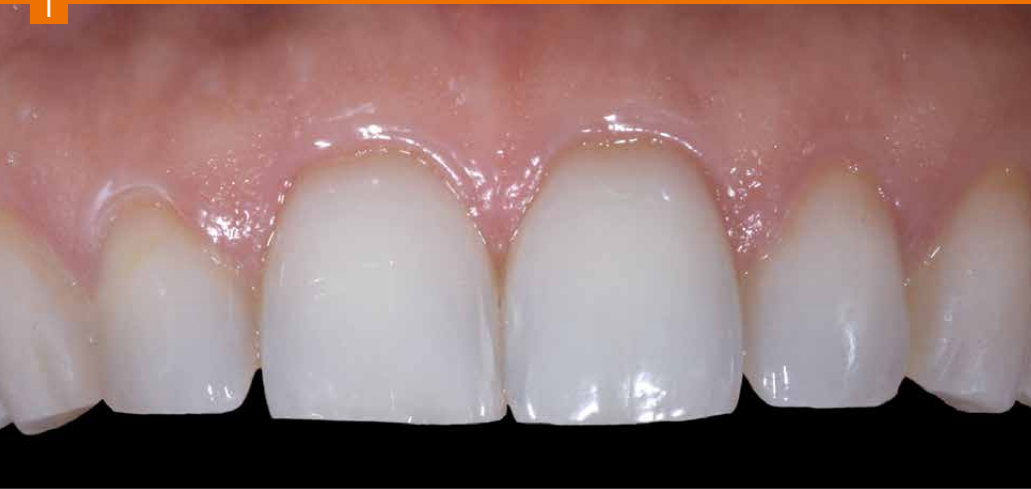This technique does not exclude any type of restoration and is suitable for the following indications:

- NON-PREP TECHNIQUE
- MINIMALLY INVASIVE PREPARATION
- INLAY-ONLAY-OVERLAY
- COMPLEX CASES WITH OR WITHOUT SUBSTRUCTURE (ALLOY-ZIRCONIUM OXIDE-GLASS FIBER-PEEK)

align

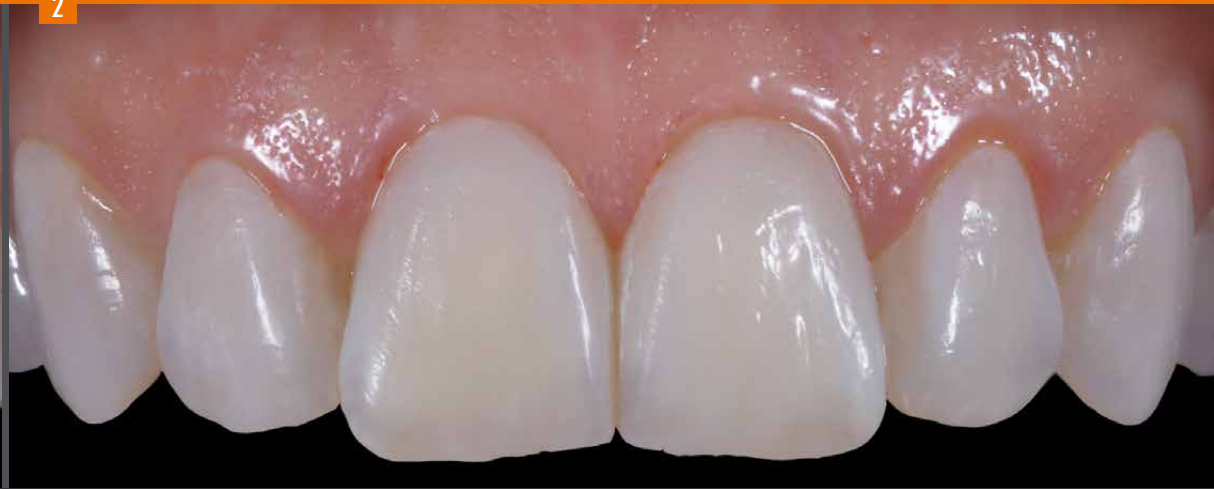Non-prep technique

1



Initial situation

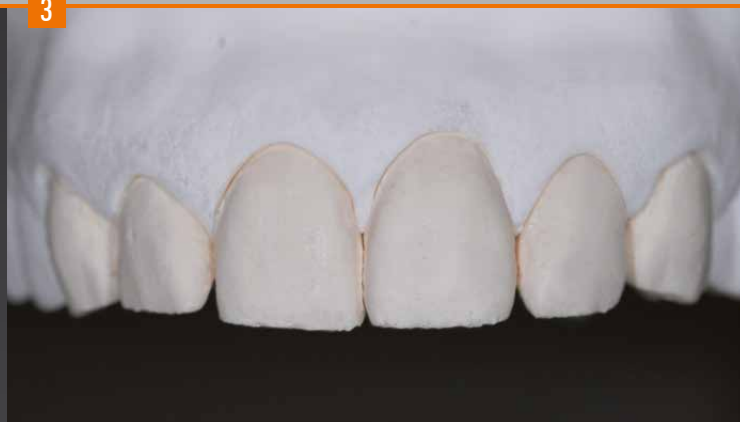2



Final result

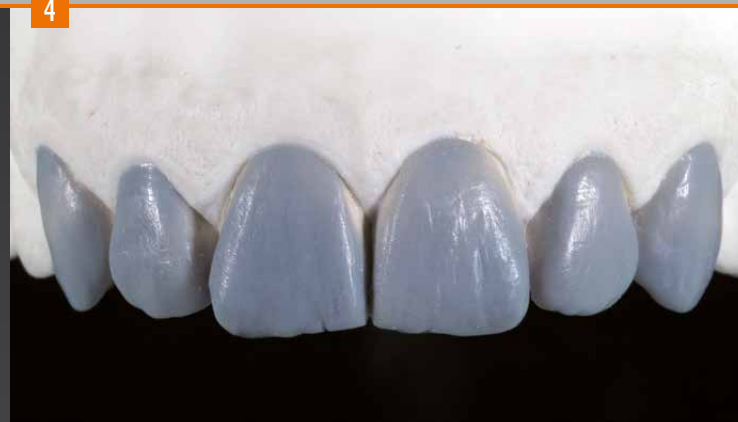Due to low cracking properties, the „additional veneering technique“ with composite material is especially suitable for cases that do not require preparation: Eventhough the patient does not identify any specific esthetic problems, it is possible to improve the function and shape of the respective teeth without an invasive procedure.

3



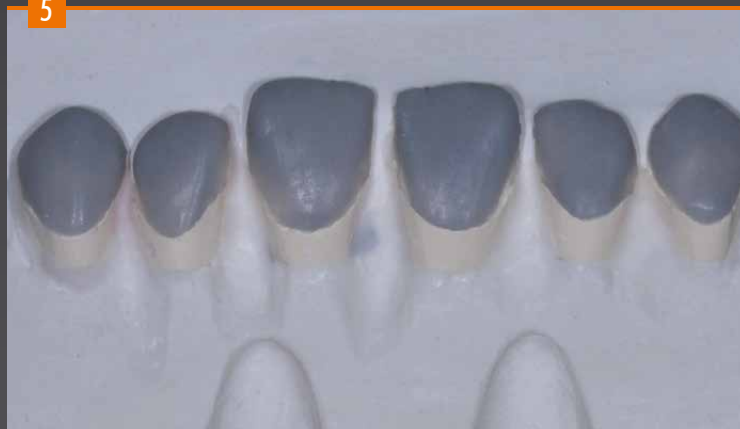The prepared master model with removable dies.

4



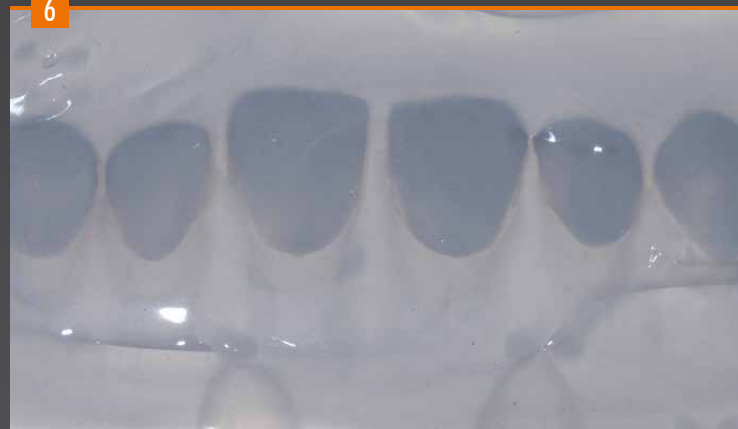Morphological wax-up of anterior teeth (wax) for the "additional veneers" ..

5



Investment (plaster) of the separated dies, including wax-up, for the manufacture of the silicone key (counterpart) for the subsequent processing steps of inverse layering.

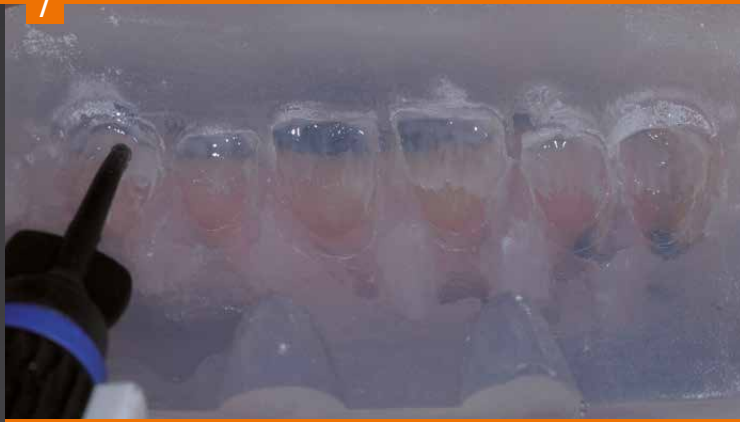6



The transparent silicone key. Hardening in the pressure pot at 2.5 bar to achieve accurate reproduction of the model.

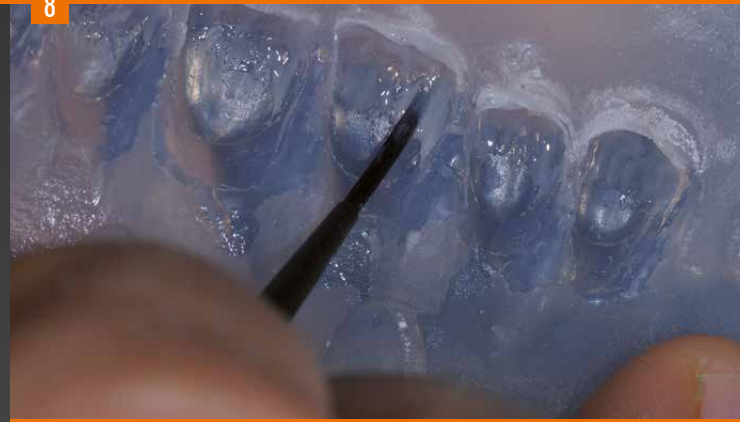Non-prep technique

7



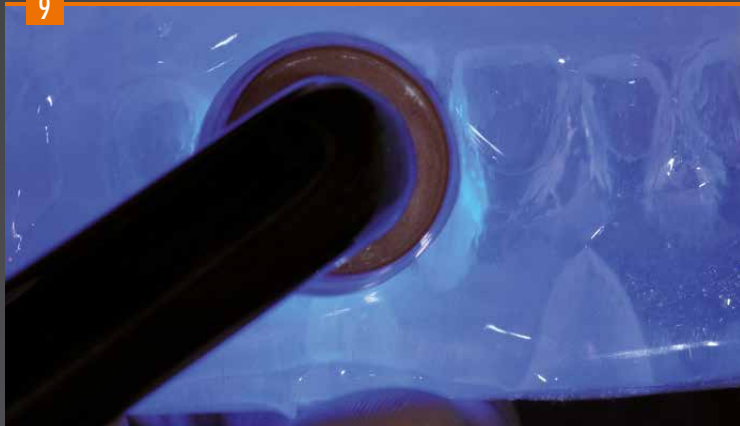
Inverse layering starts with the application of the incisal material with a high lightness value (E2) in the key.

8



The material is applied with a small brush.

9



Pre-curing for 2-3 sec. with the bre.lux hand lamp or a suitable light source.

10



Application of the effect materials to create contrasts.
Pre-curing: 2-3 sec.

11



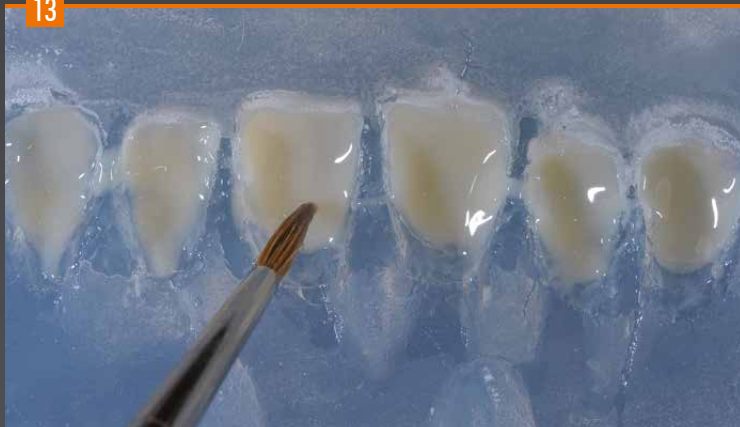Opalescent effects with the Incisal opal and Incisal blue materials, pre-curing: 2-3 sec.

12



Then a thin dentine layer (shade A1) is applied with the syringe.

13



Application of the dentine with a small brush. Placing the key onto the plaster base to complete polymerization of the composite.

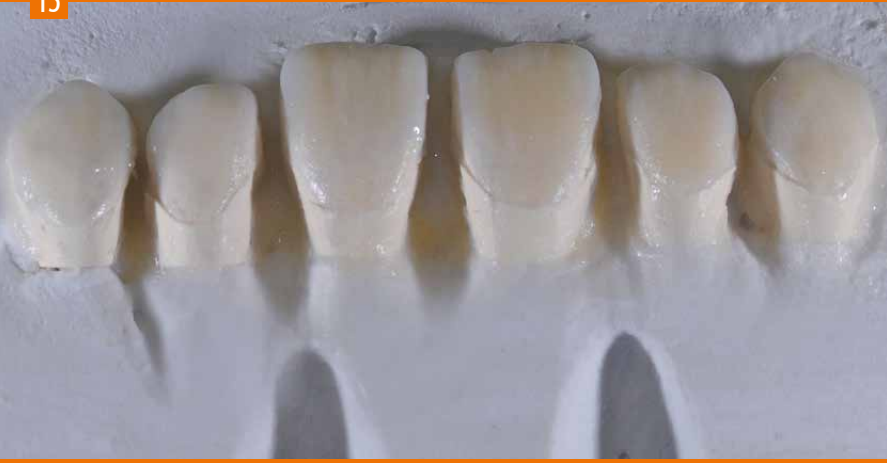14



Final curing - 360 sec. in the bre.Lux Power Unit.

Non-prep technique

15



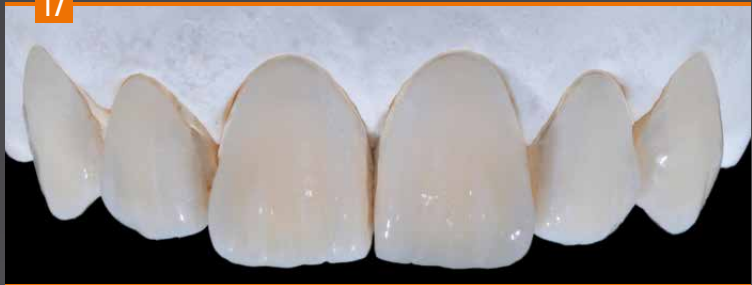Result after light curing and removal of the key.

16



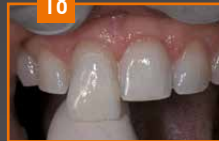The translucency of the crea.lign composite restoration..

17



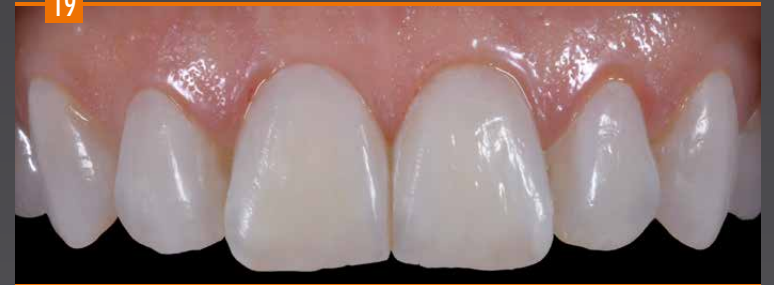The completed, finished and polished veneers on the master model.

18



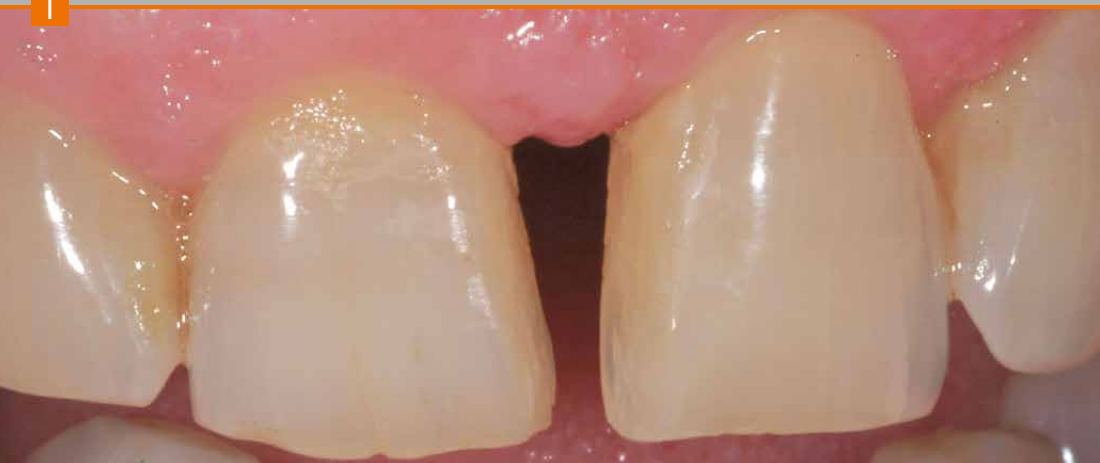Try-in of the veneers prior to insertion with a rubber dam. To check the fit, it is recommended to initially use a paste (try-in) to insert the teeth. The suitable shade of the adhesive composite is selected.

19



Veneers in situ after definitive bonding/luting.

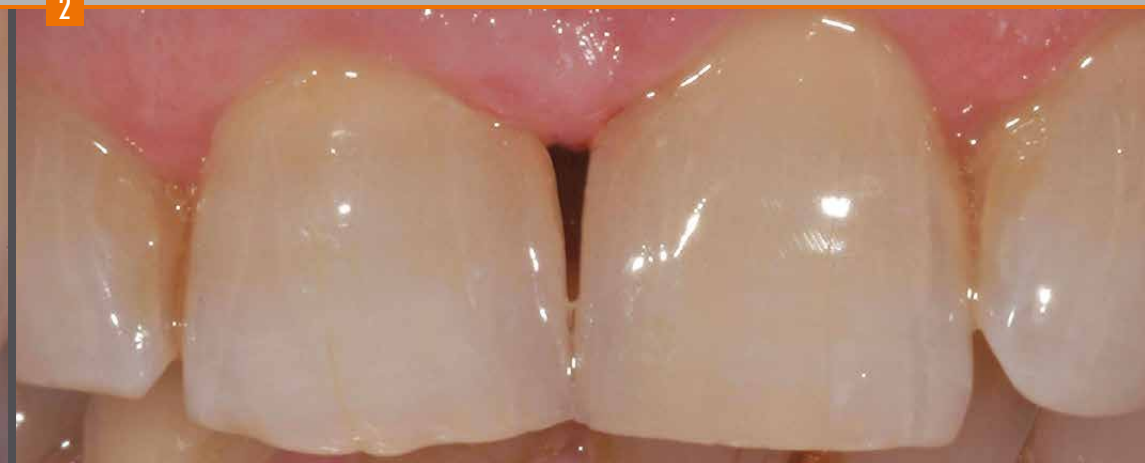1



Initial situation

Pronounced diastema between teeth 11 and 21.

2

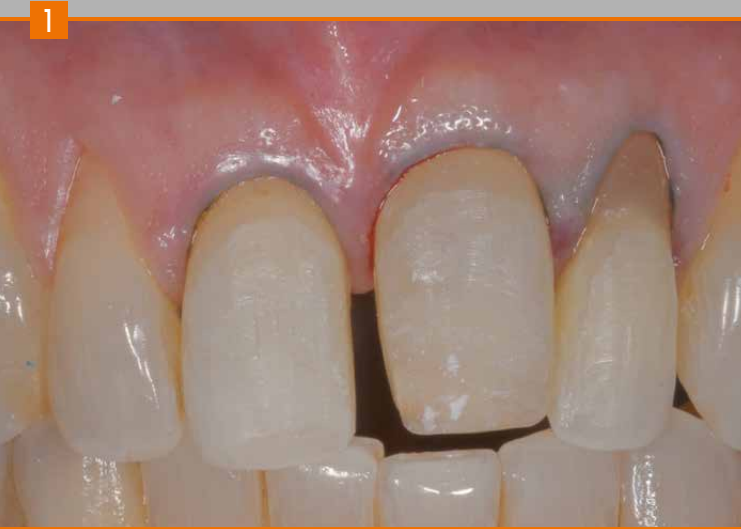

Final result

Indirect restoration made of composite and closure of diastema.

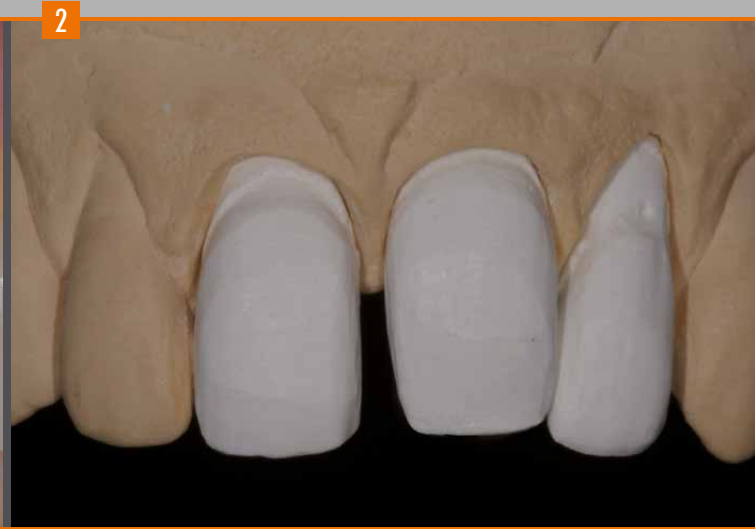As shown in the photos above, the „additional veneer technique“ is also suitable for patients with diastemas without preparation of the tooth.

Minimally invasive preparation

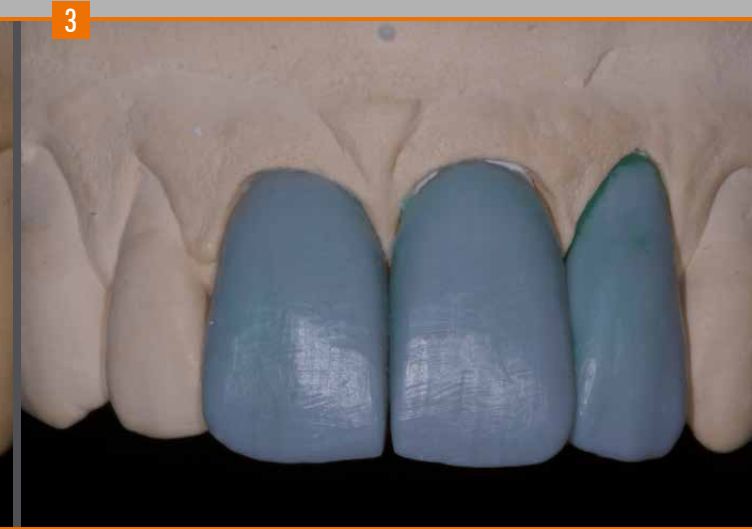

Initial situation

Minimally invasive preparation for indirect restoration with veneers (11-21-22).

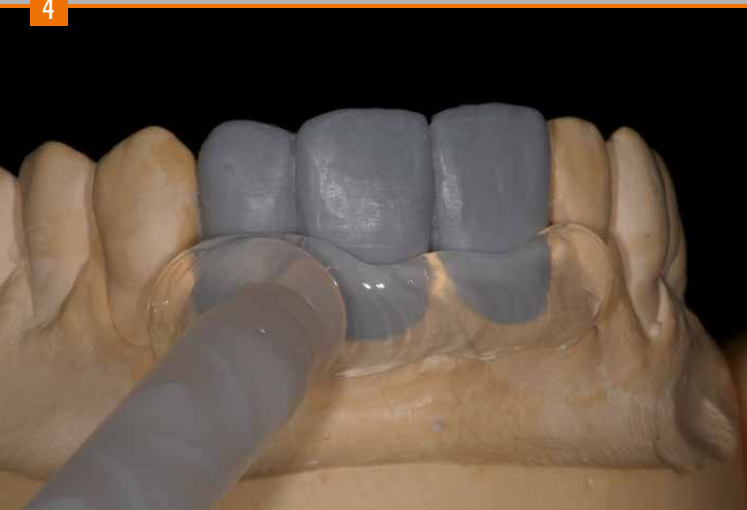

Fabrication of the master model with removable dies made of Exakto-Form polyurethane resin.



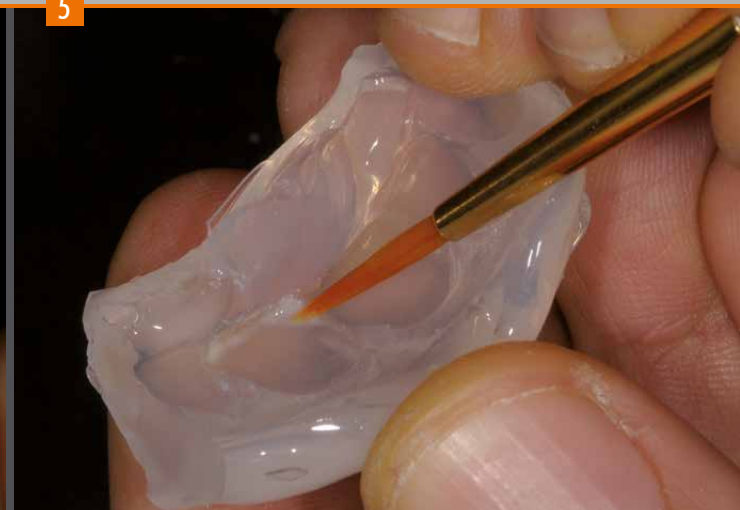Wax-up: The shape and texture of the wax model needs to include all details of the final restoration in order to reproduce them accurately in the compacted silicone key (using composite).

4



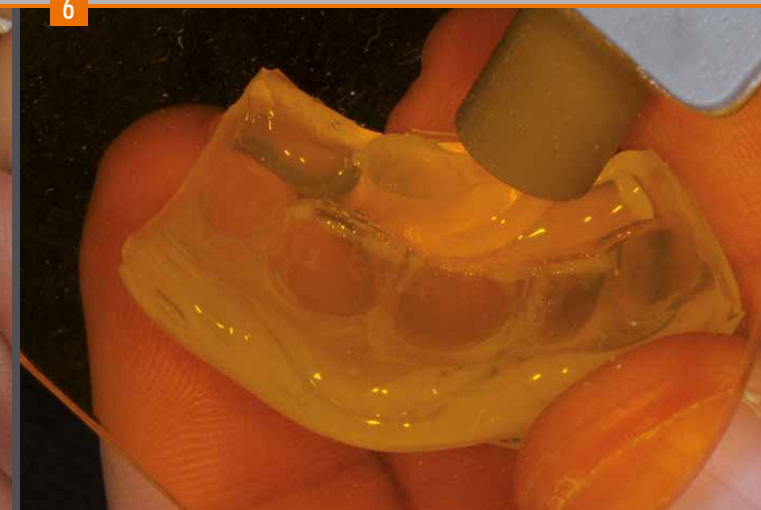
Fabrication of the key made of transparent silicone visio.sil (shore hardness 60). An optimal hardness silicone should be selected in order to avoid damaging the wax model. The silicone key should be hardened at a pressure of 2.5 bar to avoid inclusion of air and ensure maximum precision of the duplicate. Preserving the wax model enables the assessment of the layer thickness of wax to composite during inverse layering.

5



Once the silicone has hardened and the individual dies have been adequately insulated, the inverse layering technique is carried out using crea.lign. Depending on the type of reconstruction, layering starts at the incisal edge. The effect materials are applied with a small brush. The Bleach material, for example, is recommended for young teeth.

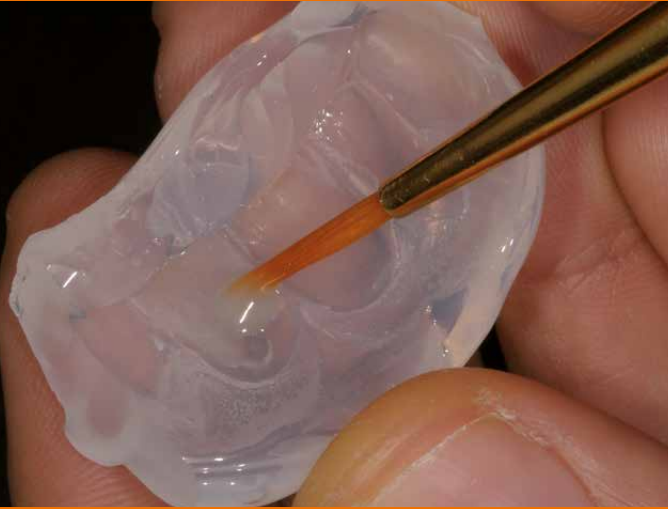
6



A pre-curing cycle (2-3 sec.) using a hand lamp is required after each individual layer to avoid individual effects mixing with other materials or with each other.

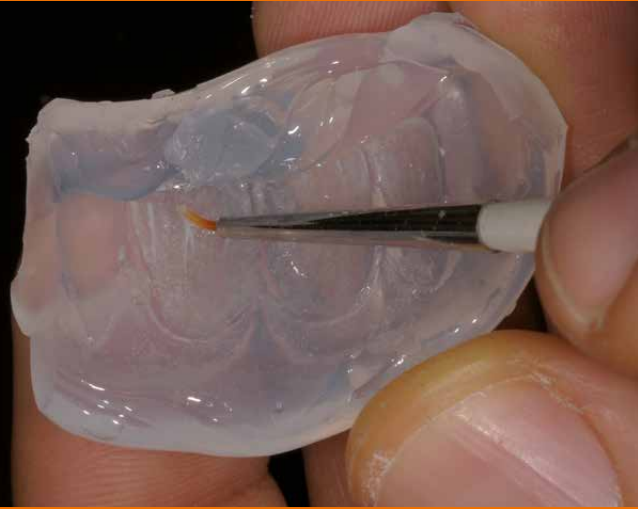Minimally invasive preparation

7



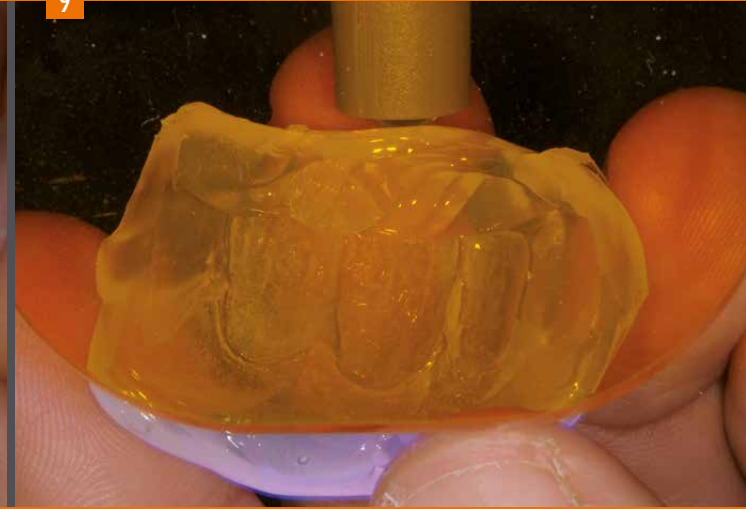
Layering can be individualized with transparent and opal effect materials according to the lightness values of the teeth. If individualization is not carried out, layering is continued with the enamel materials, as shown in photo 10.

8



The use of stains (internal stains) is another type of possible individualization. In order to imitate a crack line, for example, the use of white stain material is suggested.

9



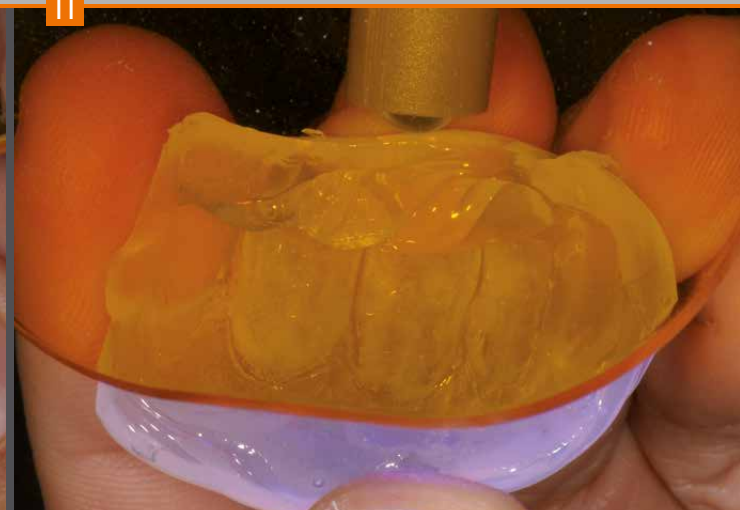
Pre-curing of the incisal effect materials.

10



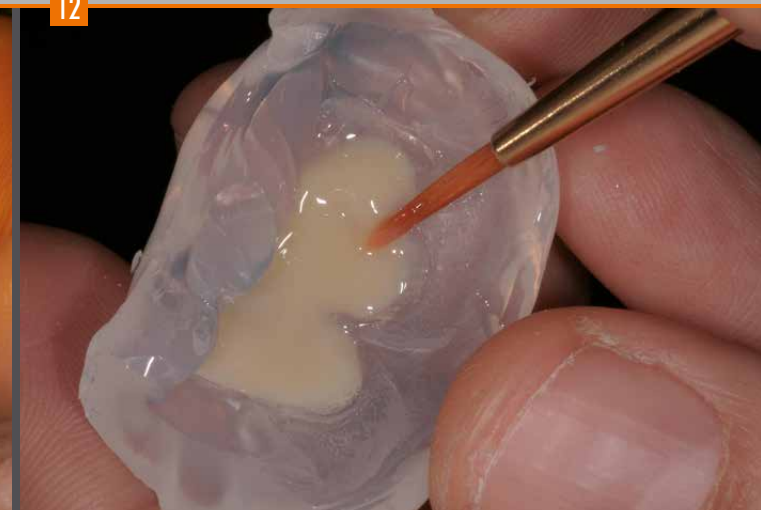In this step, the effect materials are applied in accordance with the desired color gradient.

11



Pre-curing cycle

12

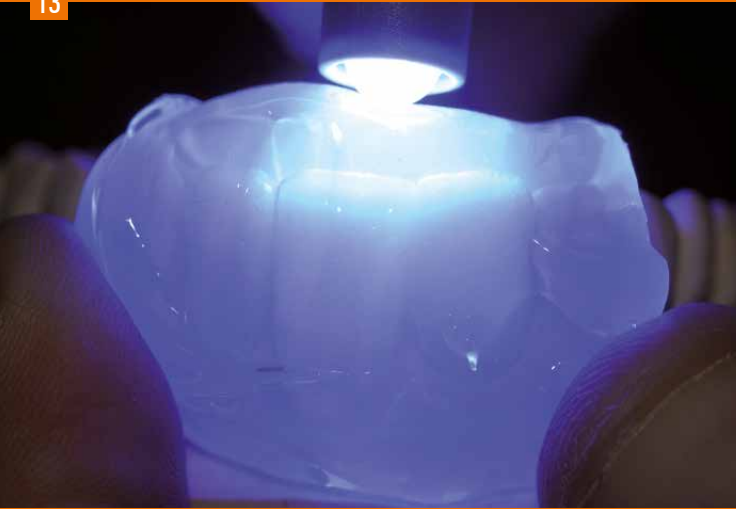

Application of dentine: while taking the layer thickness into account, it is possible to use dentine materials with different chroma levels to achieve an enhanced effect of depth.

For restorations with increasing thickness, first lighter dentine materials are applied initially to the enamel materials (↳ Layering scheme, page 56).


Minimally invasive preparation

13



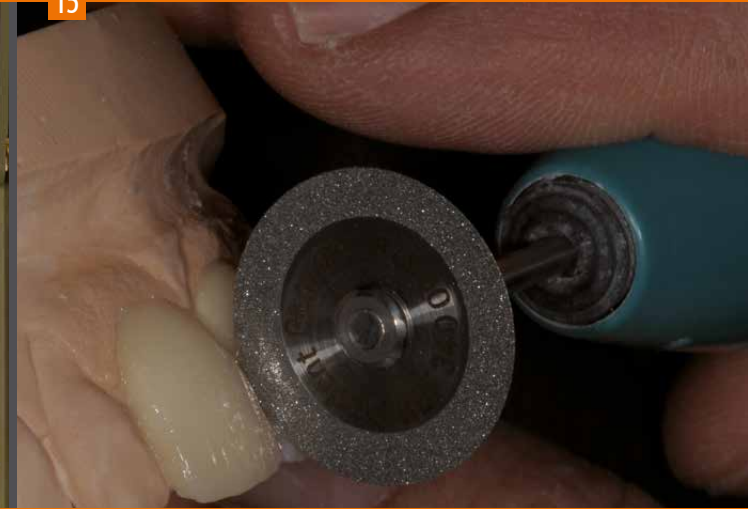
Once the key is positioned on the model, the dentine is pre-cured.

14



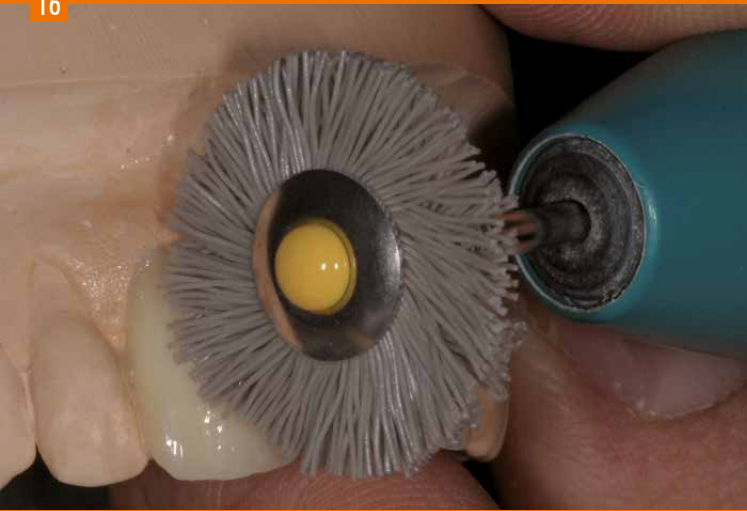
Final curing of the reconstruction in the polymerization unit.

15



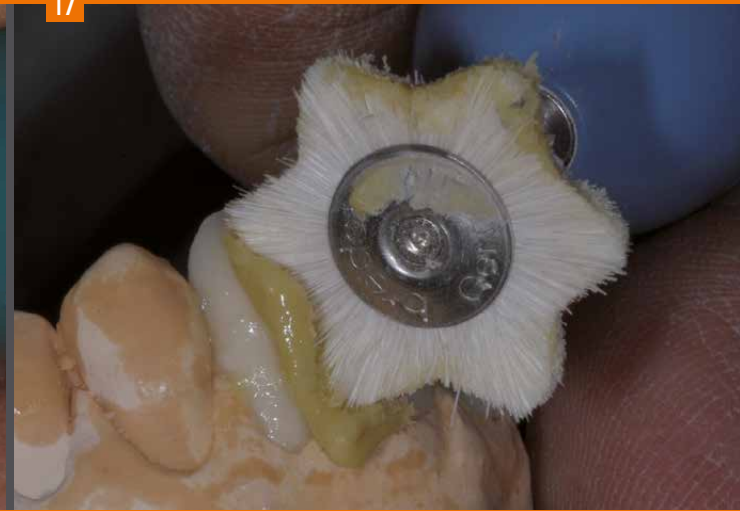After final polymerization, the silicone key enables clear recognition of the interdental separations, which can be reworked appropriately.

16



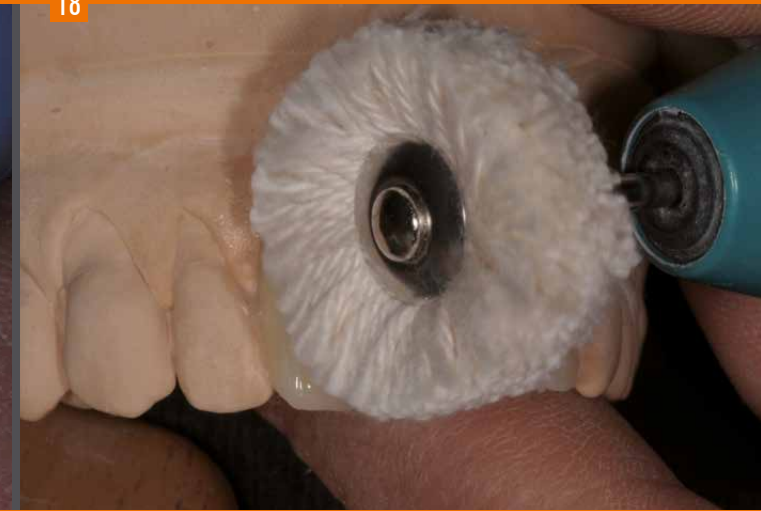Adequate preparation of the surface is important for subsequent high-gloss polishing. Use the yellow Abraso-Fix brush and at a low speed is recommended to avoid overheating the composite and „flattening“ the texture.

17



Prepolishing with a soft brush made of white goat hair and Acrypol prepolishing paste.

18



Finally, high-gloss polishing is carried out with a soft cotton map (at low speed) and Abraso-Starglanz polishing paste.

Minimally invasive preparation

19

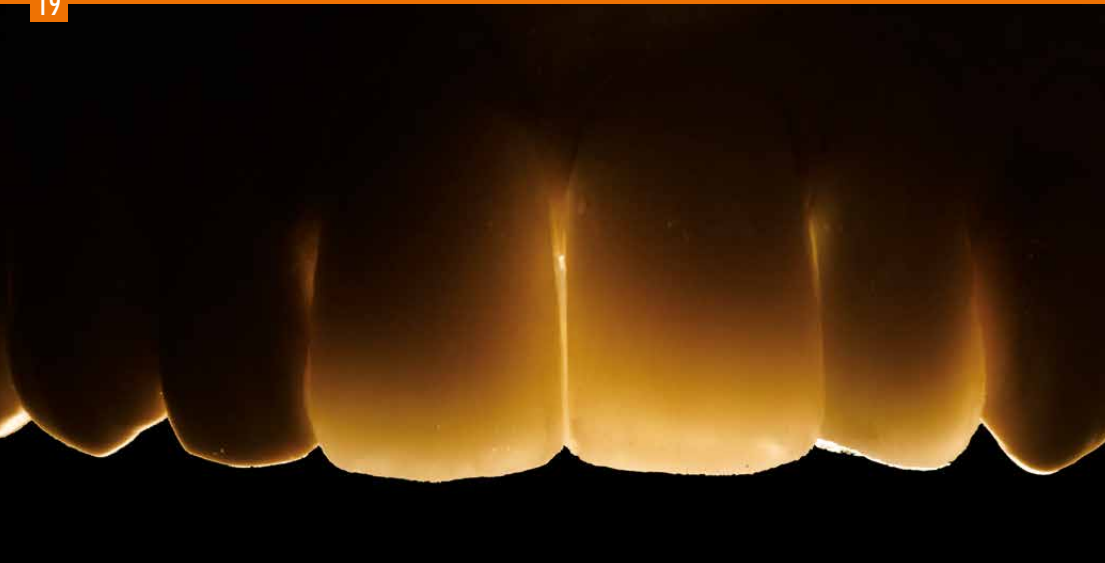
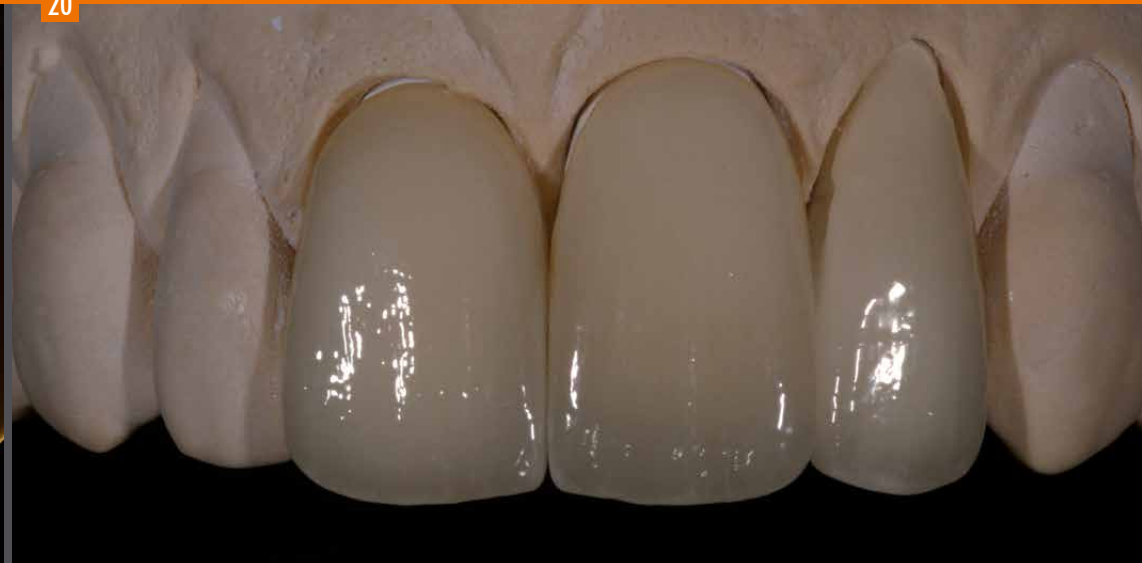
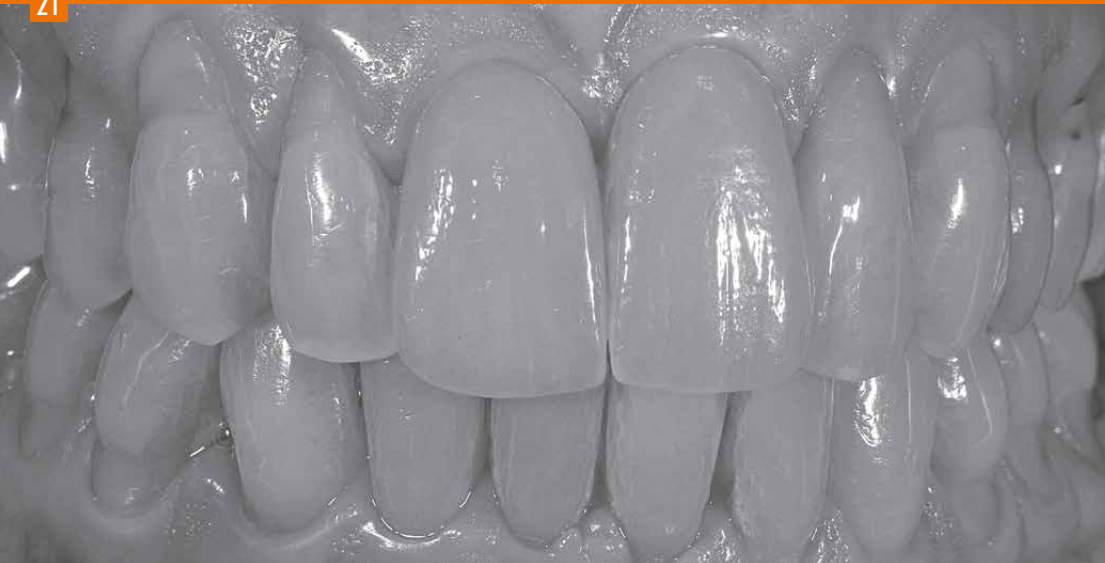Photo of the restoration on the model taken with transmitted light.
The translucency of the composite is stunning.

20



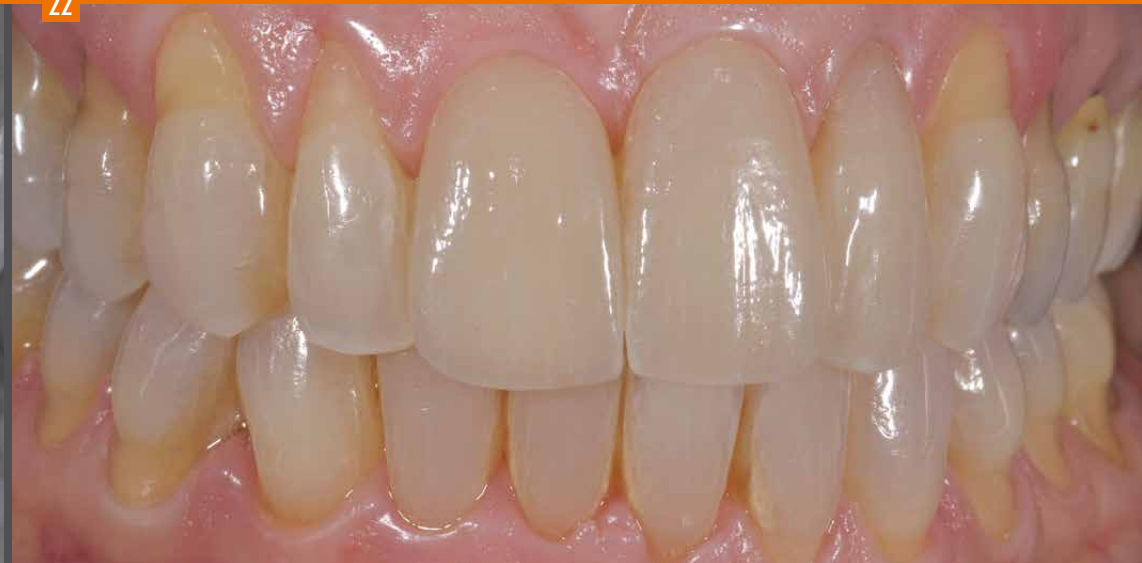The final result after high gloss polishing.

21



Black and white photo of the restoration to evaluate the shape.

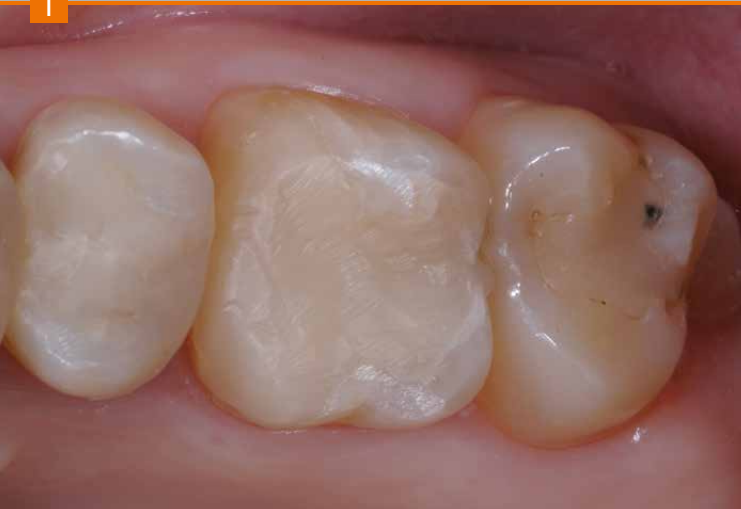22



The completed restoration in situ after adhesive bonding/luting.

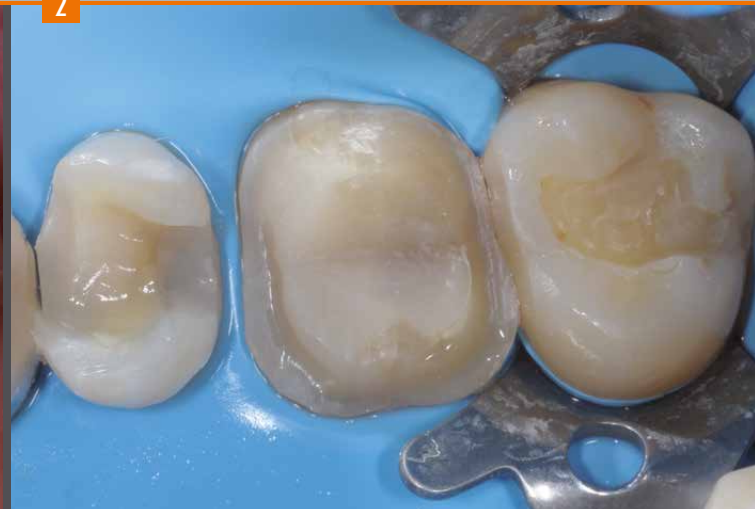Inlay Onlay Overlay

1



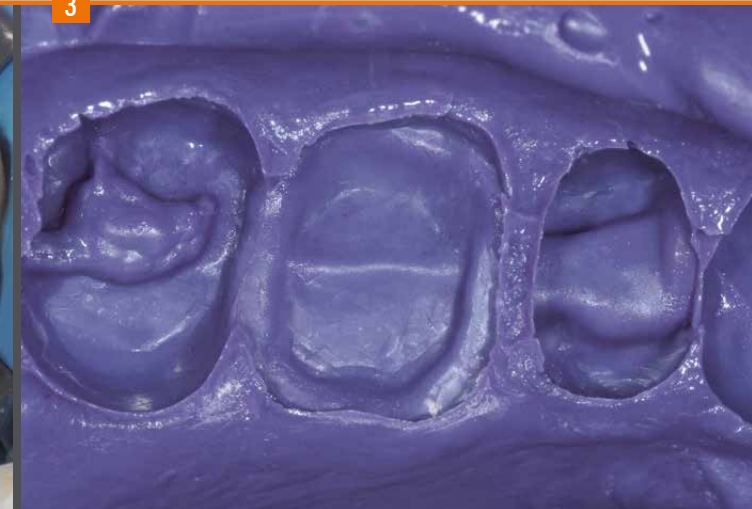Initial situation

2



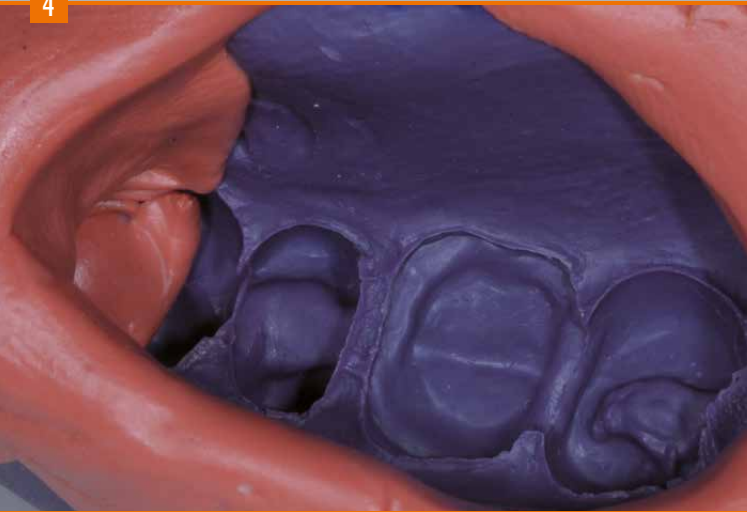
Preparation of the teeth.
MOD inlay on tooth 25, full crown on tooth 26 and
inlay on tooth 27.

3



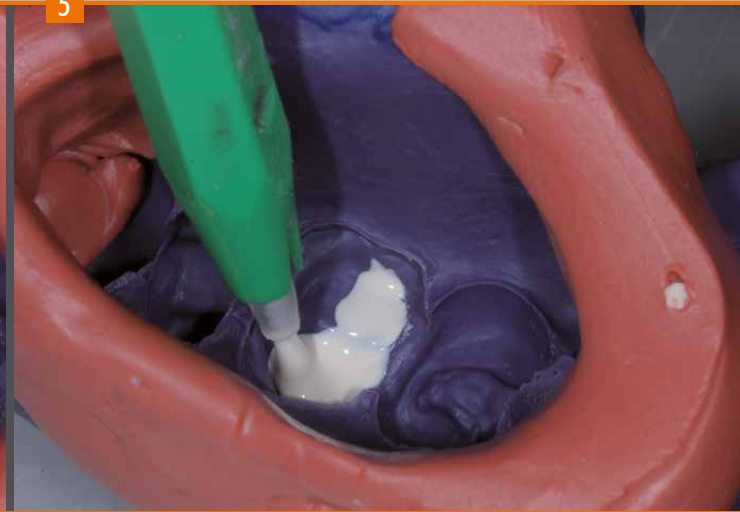Details of the polyether impression.

4



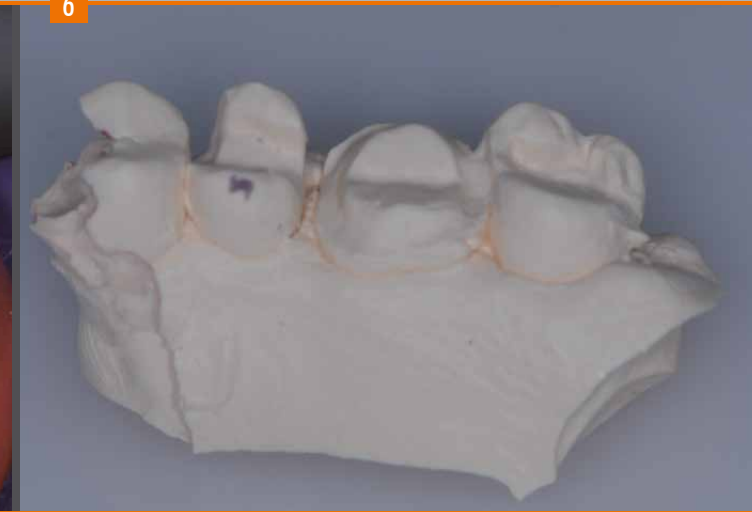Blocking out the impression: this step is required since the dies are made of polyurethane resin which has a low viscosity (highly liquid properties) during pouring.

5



To prepare a bubble-free model, it is recommended to fill the cavities with Exakto Form using a small brush.

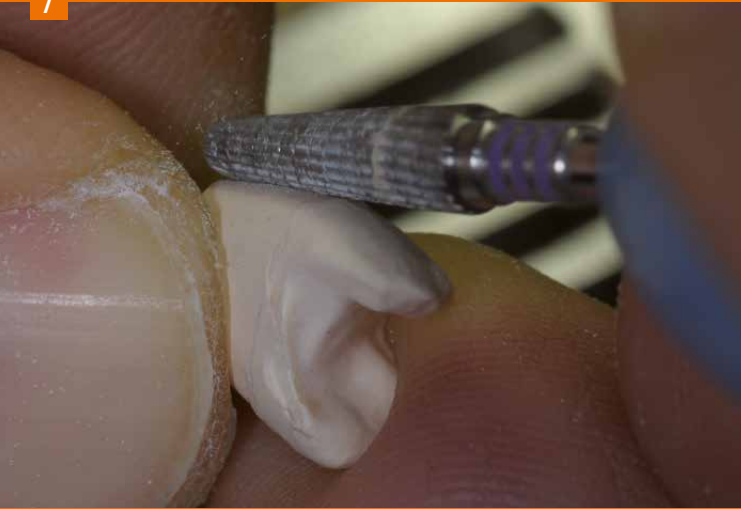6



The model can be removed from the mould and adjusted after 45 minutes.

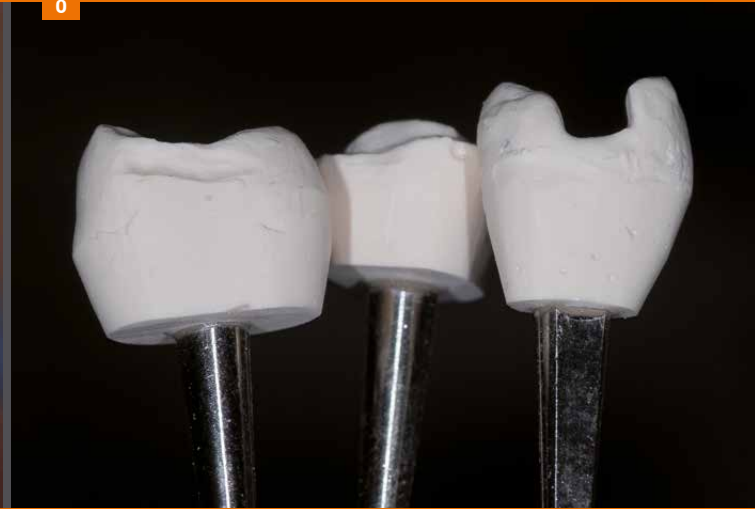Inlay Onlay Overlay

7



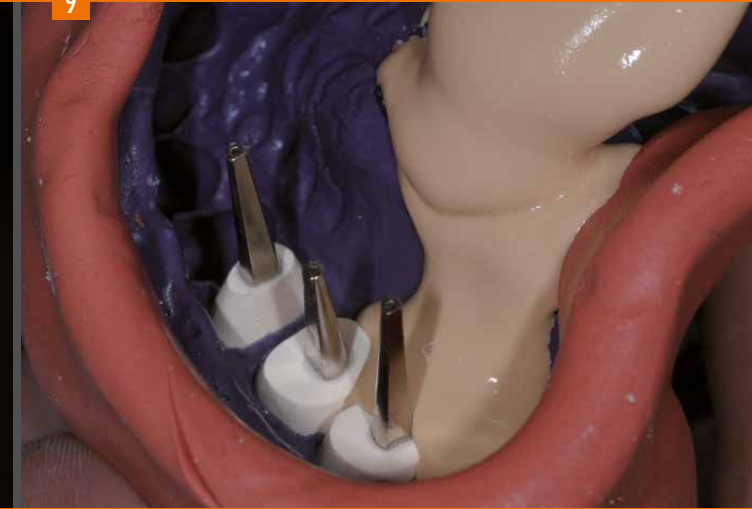Once the complete model has been poured, the individual dies are separated and prepared adequately.

8



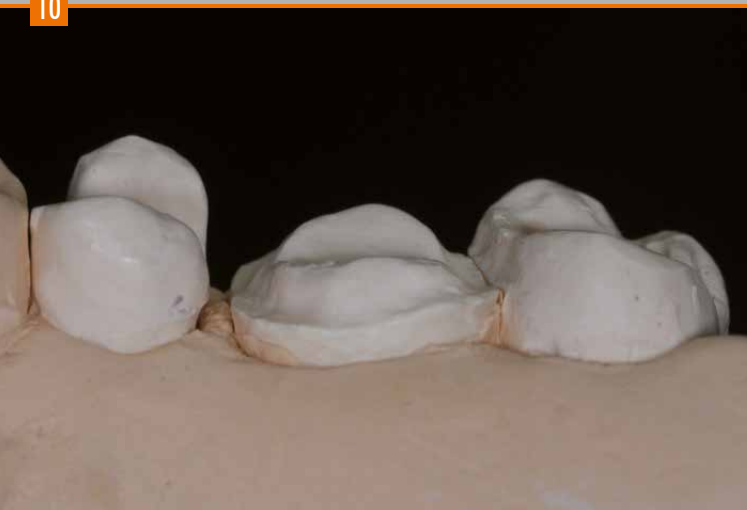The individual, prepared dies are insulated.

9



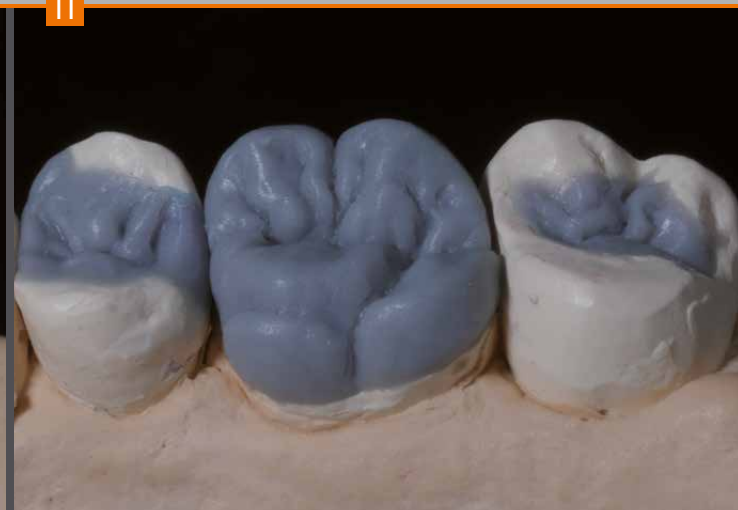The prepared and insulated dies are repositioned in the impression, which is then filled with stone for the fabrication of the master model.

10



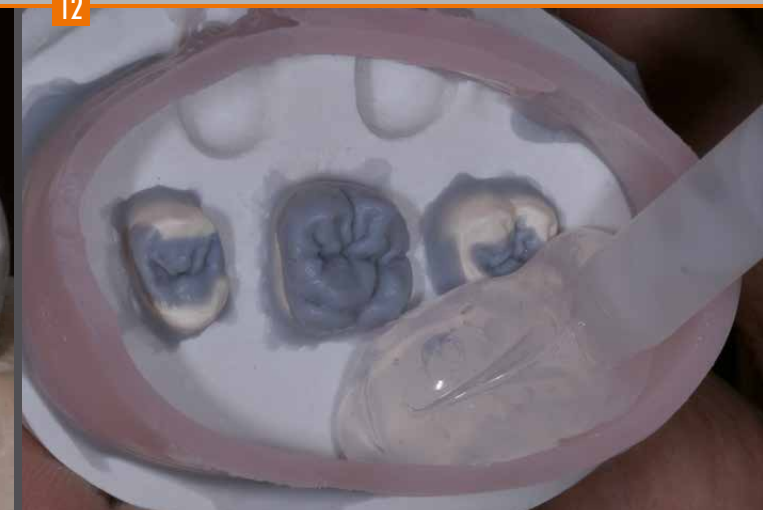The master model prepared in this way maintains the biological height of the emergence profiles and enables easy removal of the respective dies made of Exakto-Form polyurethane resin.

11



Anatomical wax model of the indirect restorations: MOD inlay on tooth 25, full crown on tooth 26 and inlay on tooth 27.
When waxing-up the occlusal surfaces, the fissures are deeper and larger to individualize layering with stains in the final finish.
(↳ page 27)

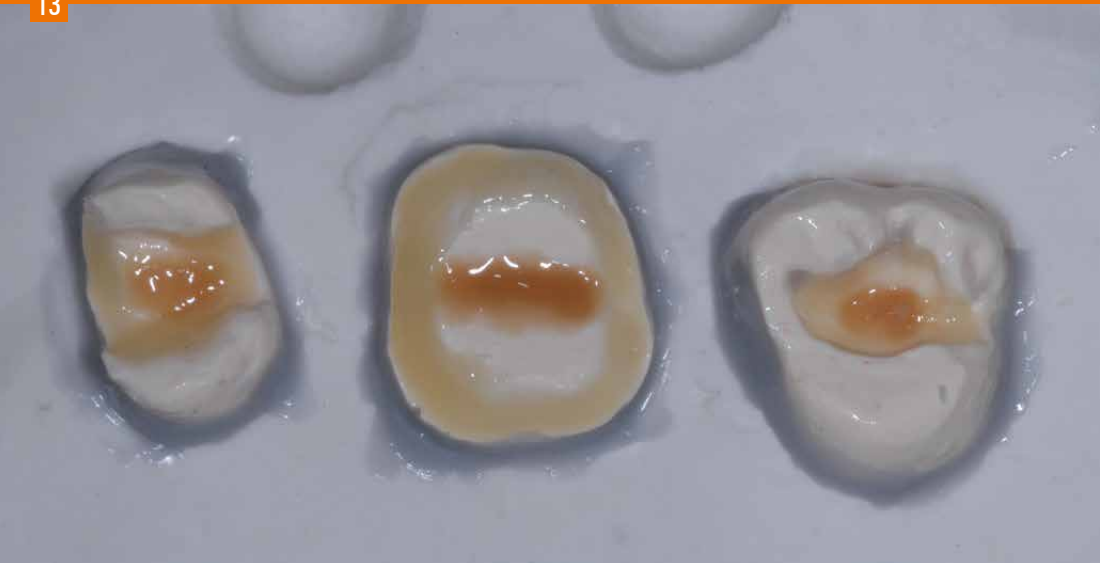12



A separate plaster base is created for the individual dies with anatomical wax-up. This transfer base is invested for the injection of the transparent silicone. The silicone is then compacted at a pressure of 2.5 bar to reproduce all details of the wax model in a highly accurate manner.

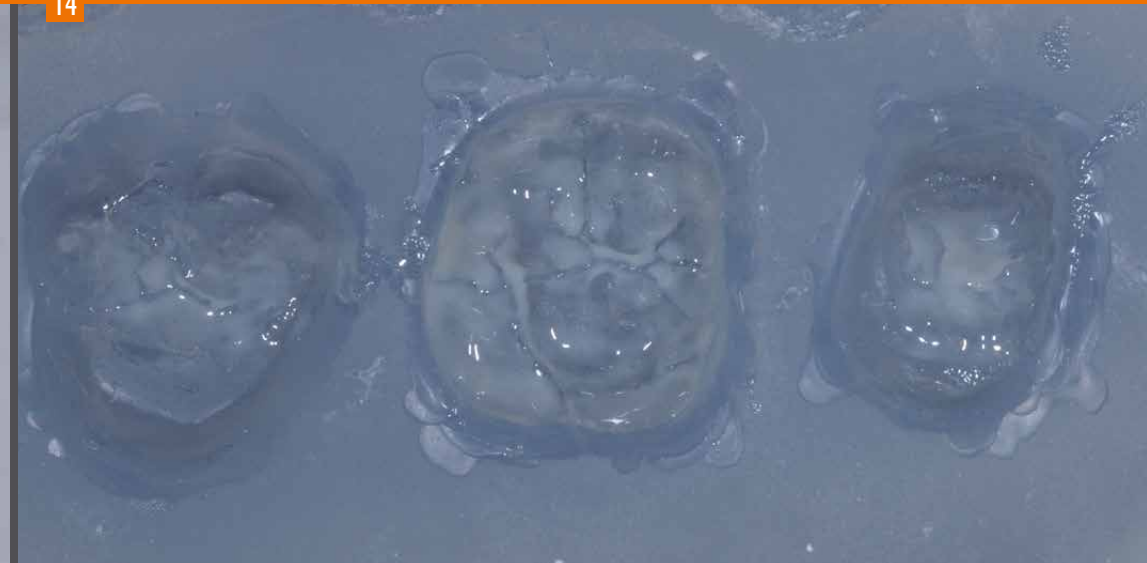Inlay Onlay Overlay

13



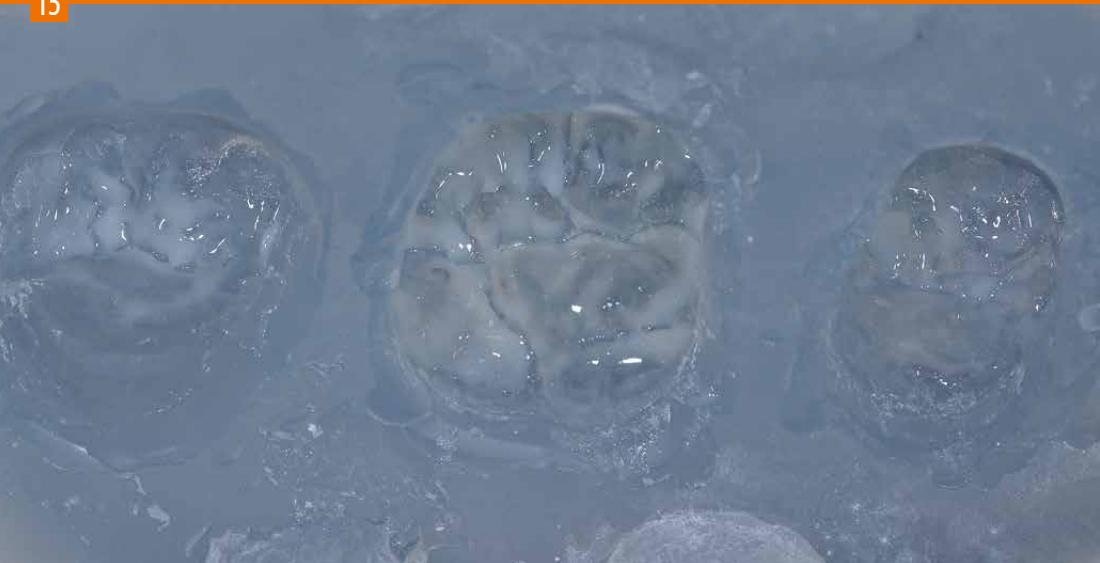Application of a very thin dentine layer to the die, which is subsequently coated with the „Caramel“ modifier to achieve an enhanced effect of depth and to mask the light core build-up.

14



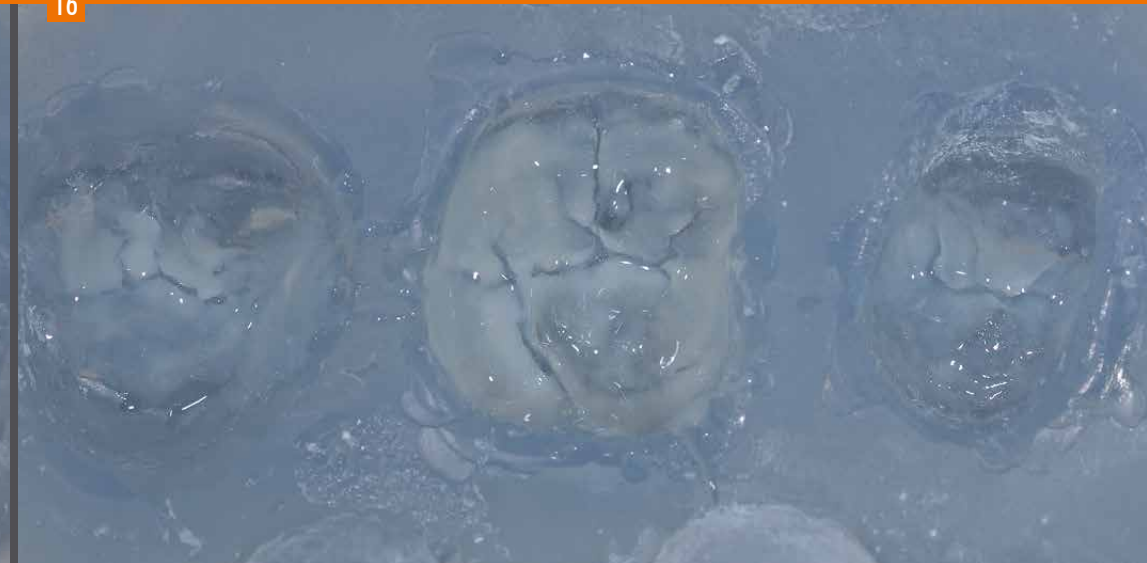Application of the bleach material into the key to „emphasize“ the marginal ridges of the tooth.

15



Increasing the opal effects with the Incisal blue or Incisal opal materials.

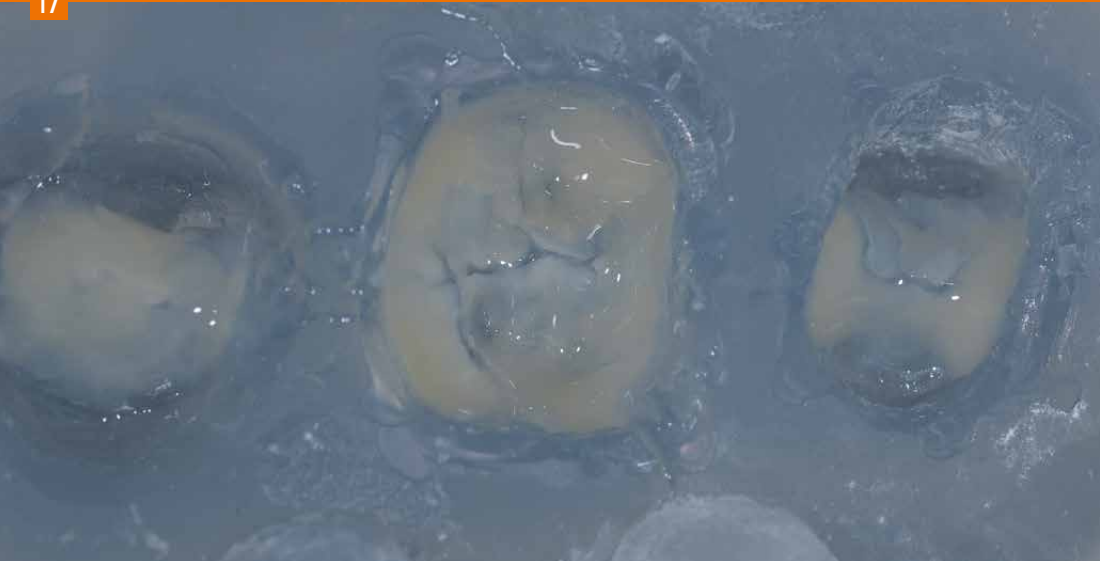16



After pre-curing the Bleach material and the Incisal blue material, apply a small quantity of E2 incisal material.

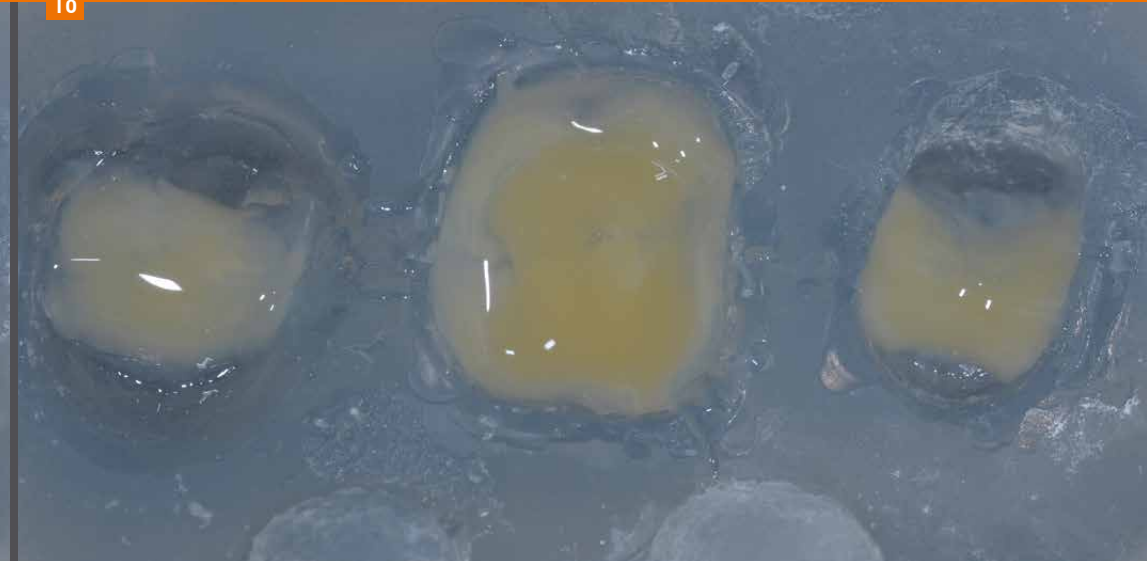Inlay Onlay Overlay

17



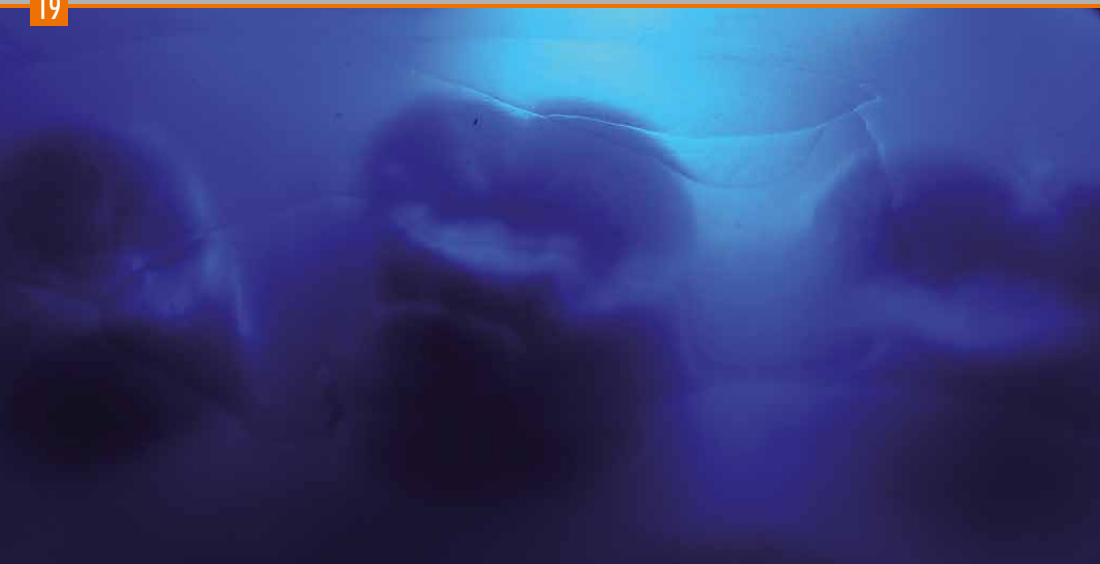Dentine layering: Depending on the total thickness of the restoration, two or three different dentine shades are applied to increase the effect of depth of the tooth (↳ Layering scheme, page 56).
Initially, dentine materials A1 and A2 are applied as primary dentine.

18



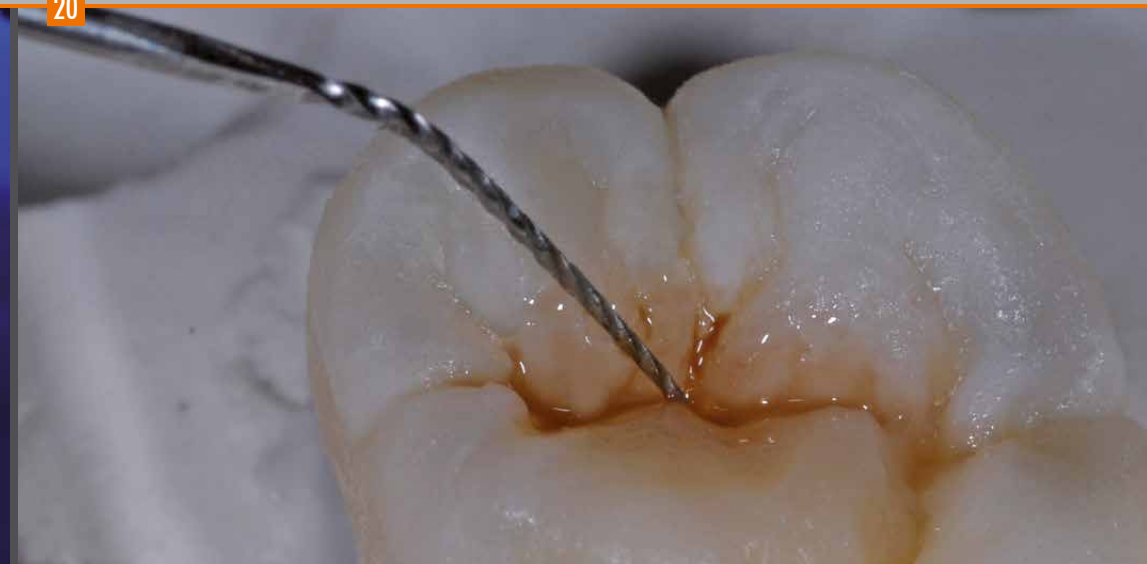Application of the secondary dentine of the selected tooth shade A3 with higher chroma.

19



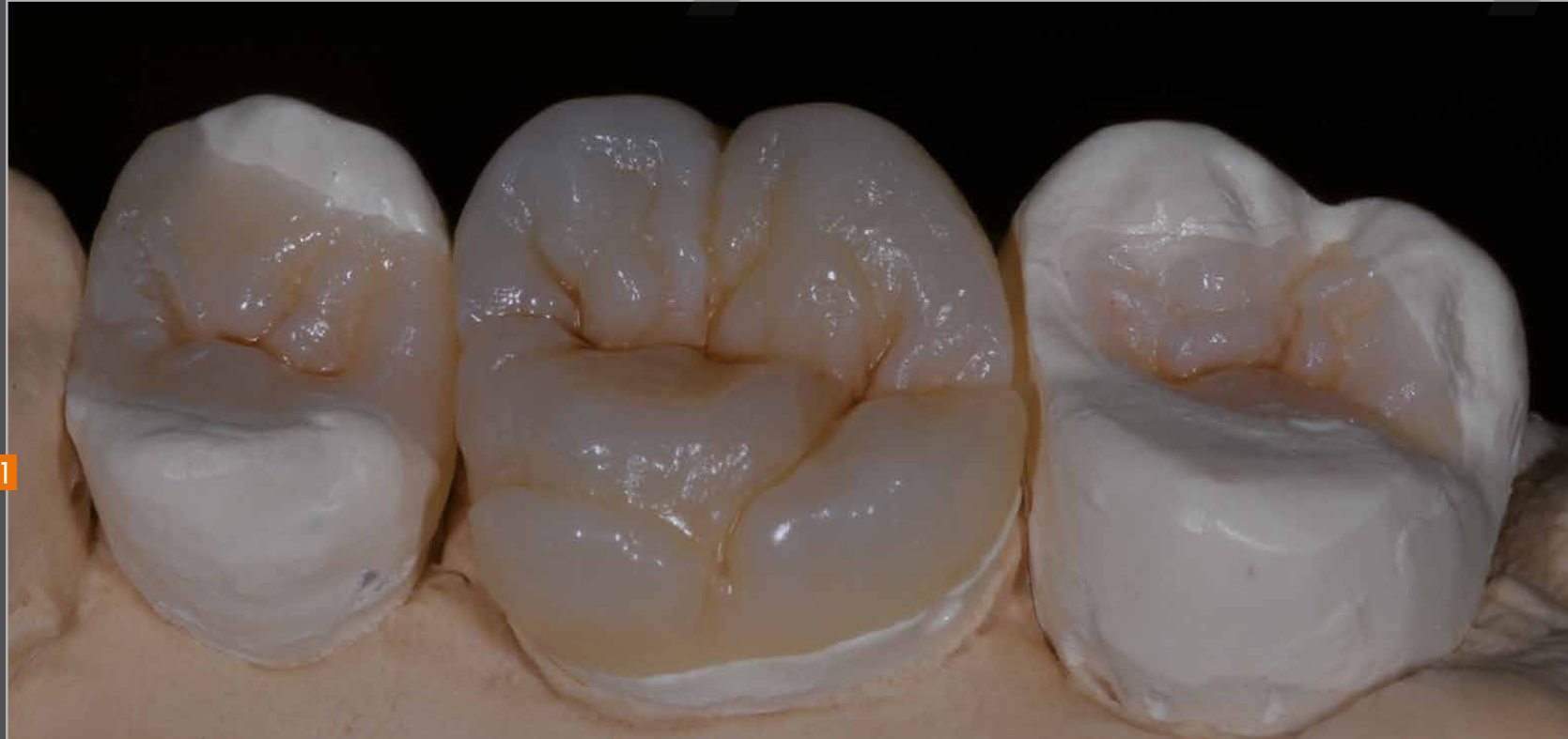Repositioning the silicone key on the plaster base with dies and pre-curing.

20



After pre-curing, the composite restorations are characterized with stains to „intensify“ fissures and pits of the occlusal surfaces. In the main fissure, for example, brown and orange stains are used to achieve an enhanced effect of depth. crea.lign stains can be directly applied and do not need to be overlayed (coated). The restoration is finished and polished as shown on page 17 after final curing in the bre.Lux Power Unit (360 sec.).

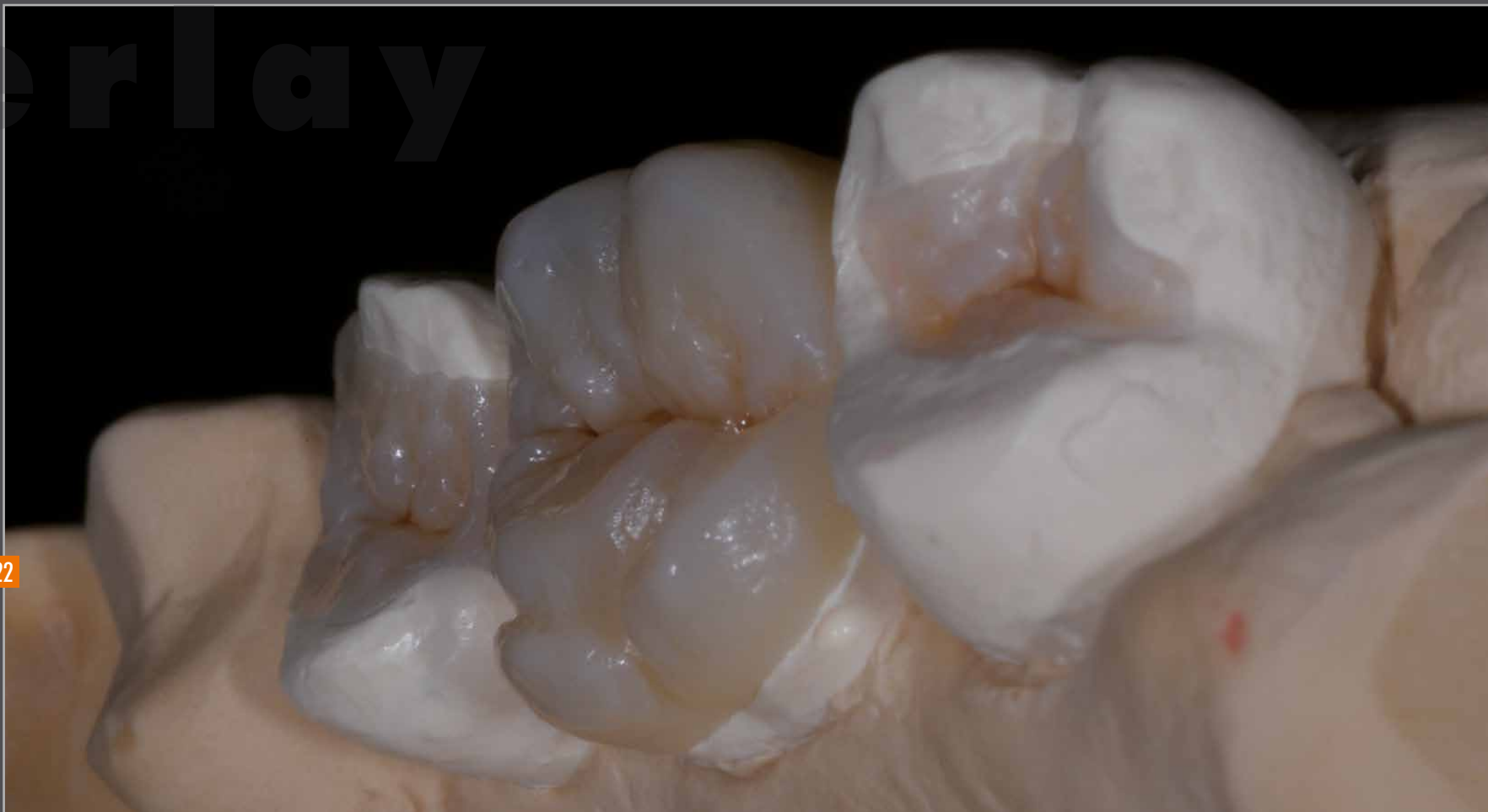Inlay Onlay Overlay



21

overlay

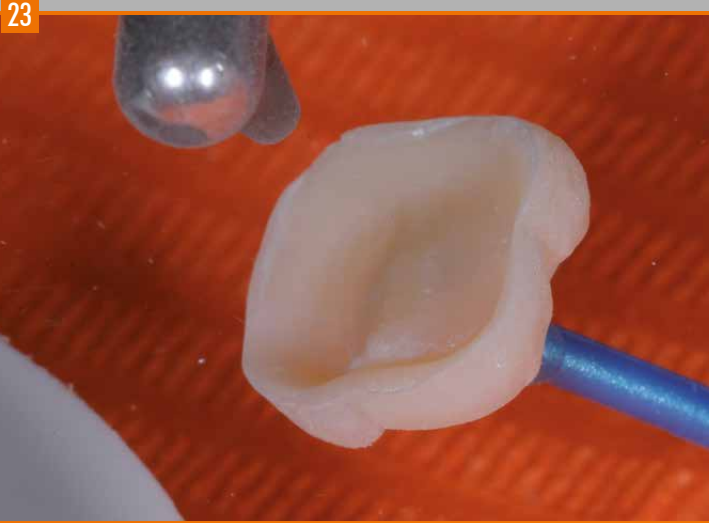
22



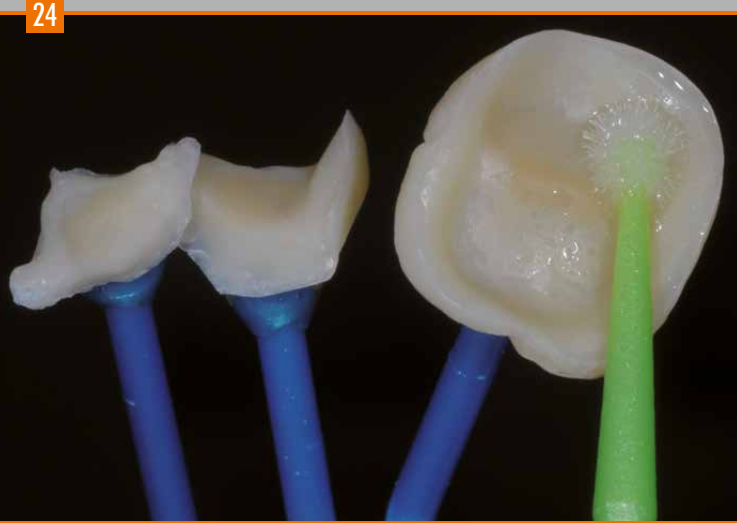
Completed and polished restorations on the master model.

bredent
group

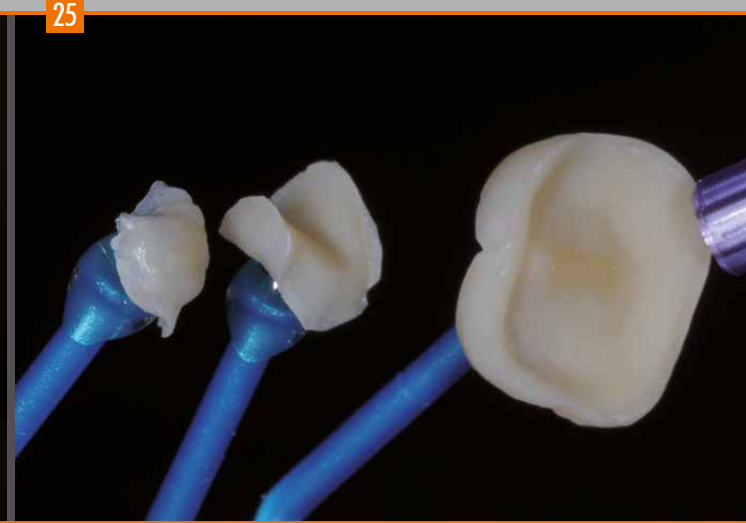
Inlay Onlay Overlay



The indirect restorations are sandblasted with aluminium oxide ($50\text{ }\mu\text{m}$) prior to adhesive bonding/luting to the teeth.

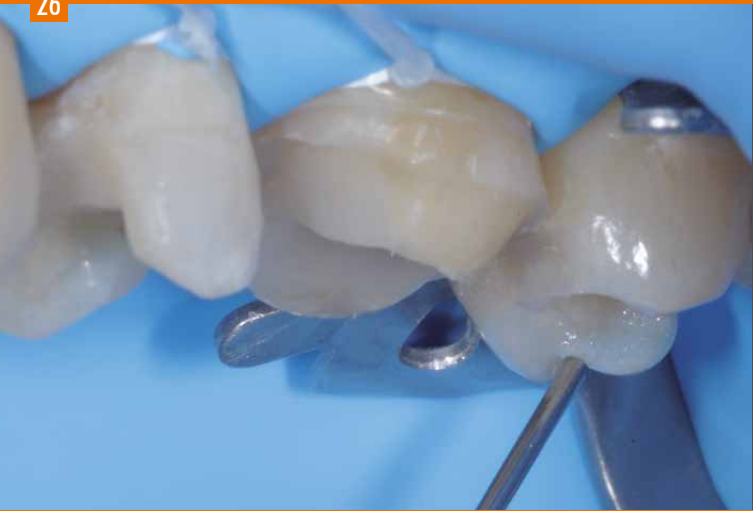

Careful cleaning of the indirect restorations with methylated spirit (ethanol colorless).



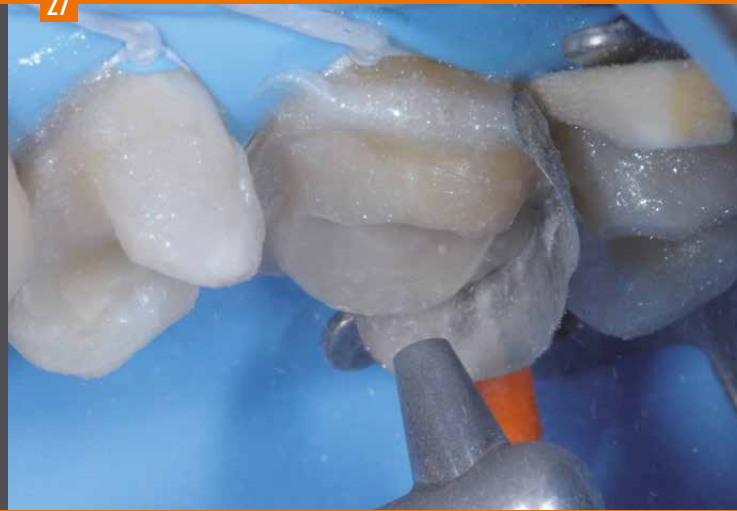Drying the indirect restorations with air.

26



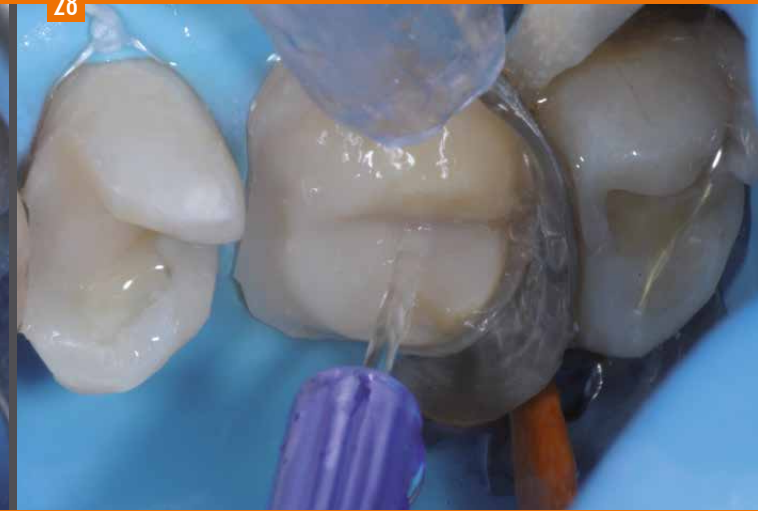A gel-like film is used for marginal protection of the part of the tooth not to be restored.

27



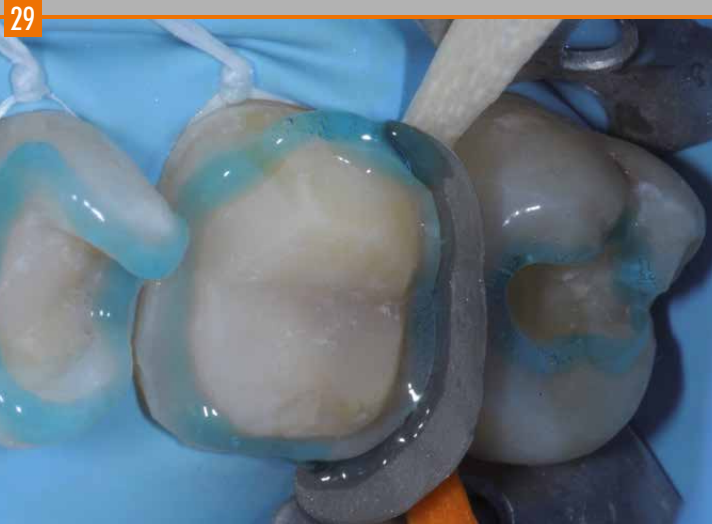Sandblasting the preparations using aluminium oxide (50 μ m).

28

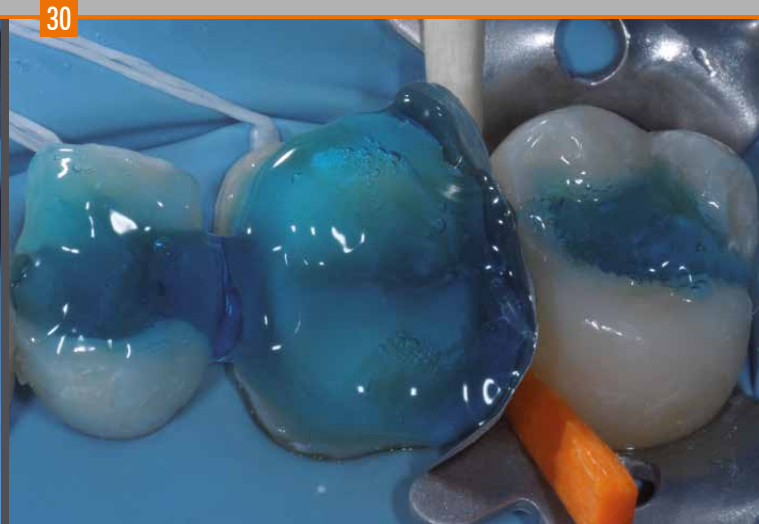

Careful cleaning to remove any residual aluminium oxide.

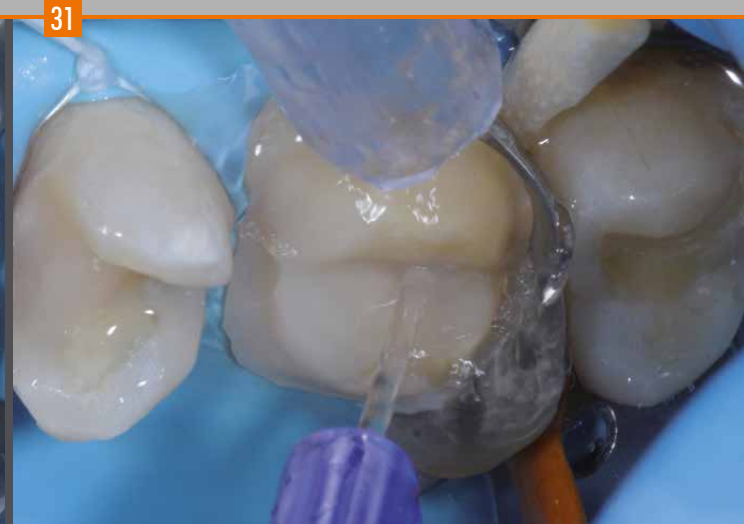Inlay Onlay Overlay



Selective etching of the tooth enamel for 15 sec.

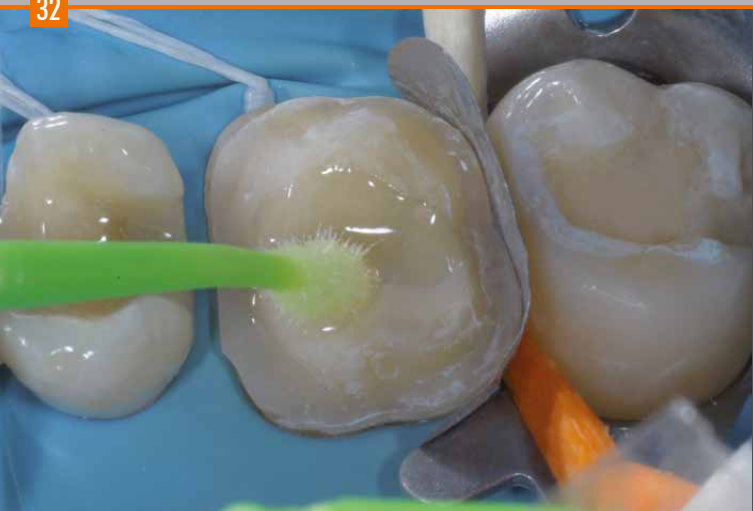

Dentine etching for 15 sec.



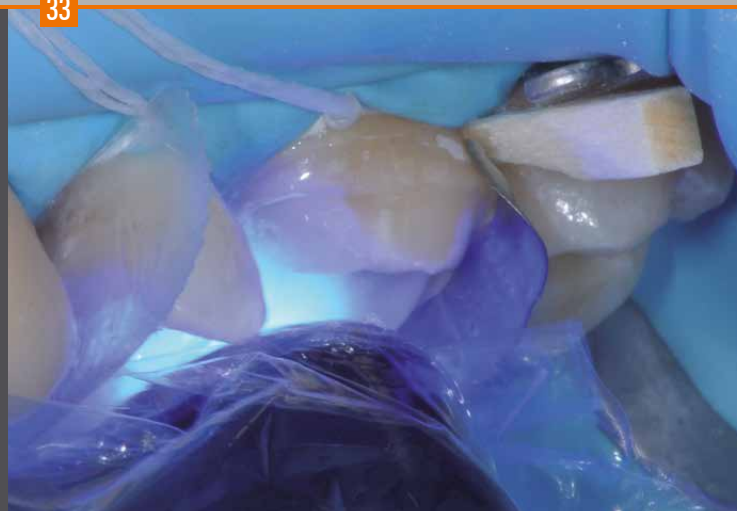Careful cleaning with water to remove any acid residues.

32



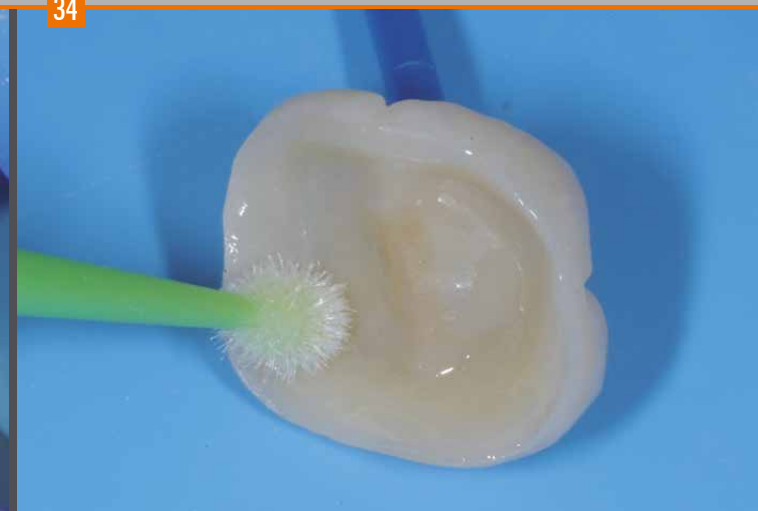Application of the adhesive to the preparations. Each adhesive features specific processing guidelines need to be strictly adhered to.

33



Polymerization (light curing) of the adhesive.

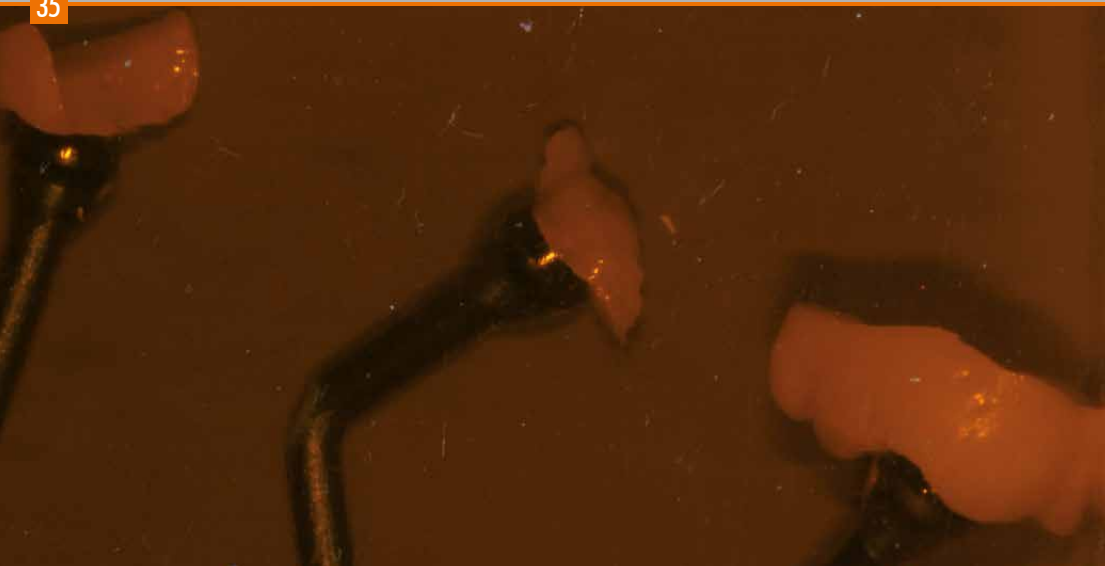34



Optionally, a primer / bonder is applied thinly to the restoration. This is only necessary if the restoration was completed more than 24 hours ago. The crea.lign Modelling Liquid can be used for this purpose.

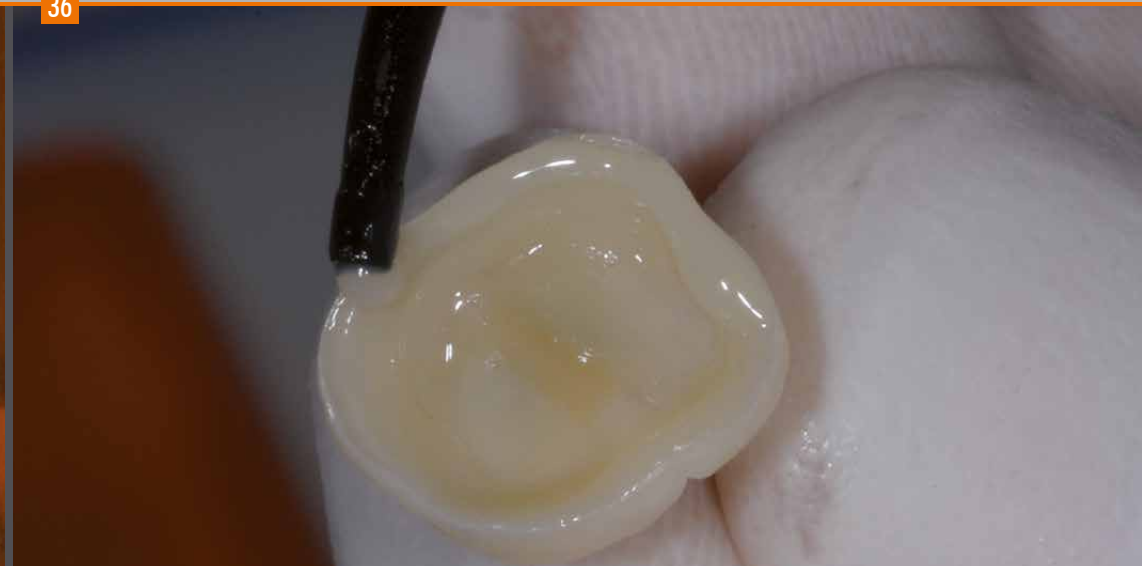Inlay Onlay Overlay

35



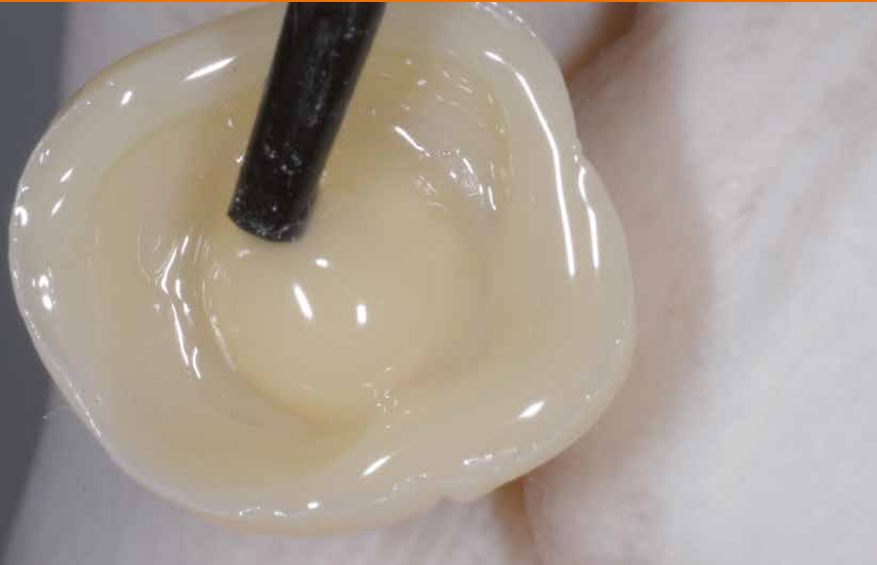During the processing steps described below, it is recommended to protect the restorations with the applied adhesive against light to avoid premature curing.

36



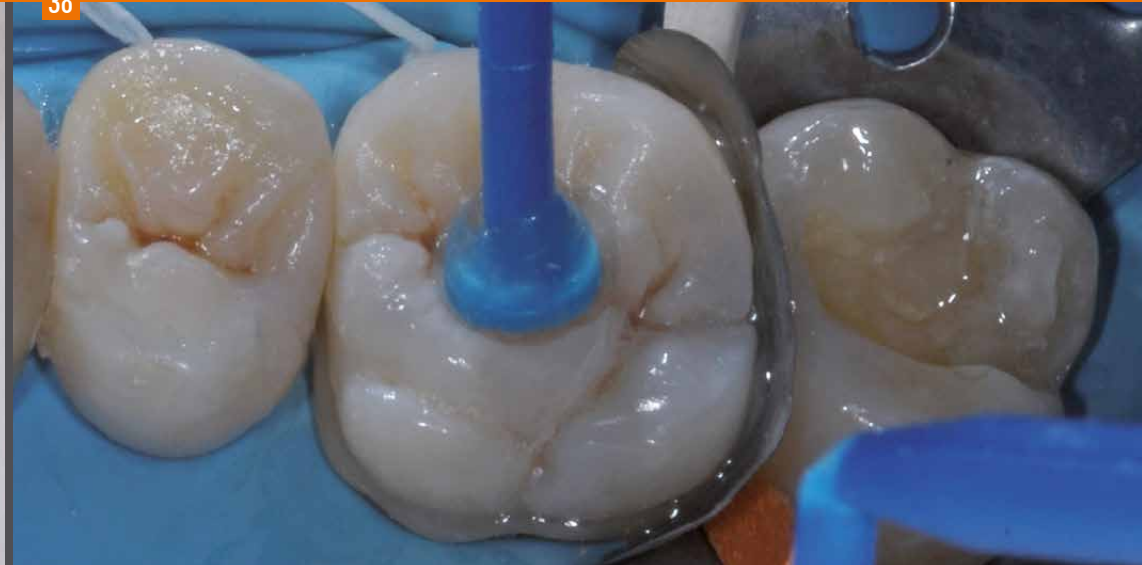Application of the incisal material to the marginal areas of the restoration.

37



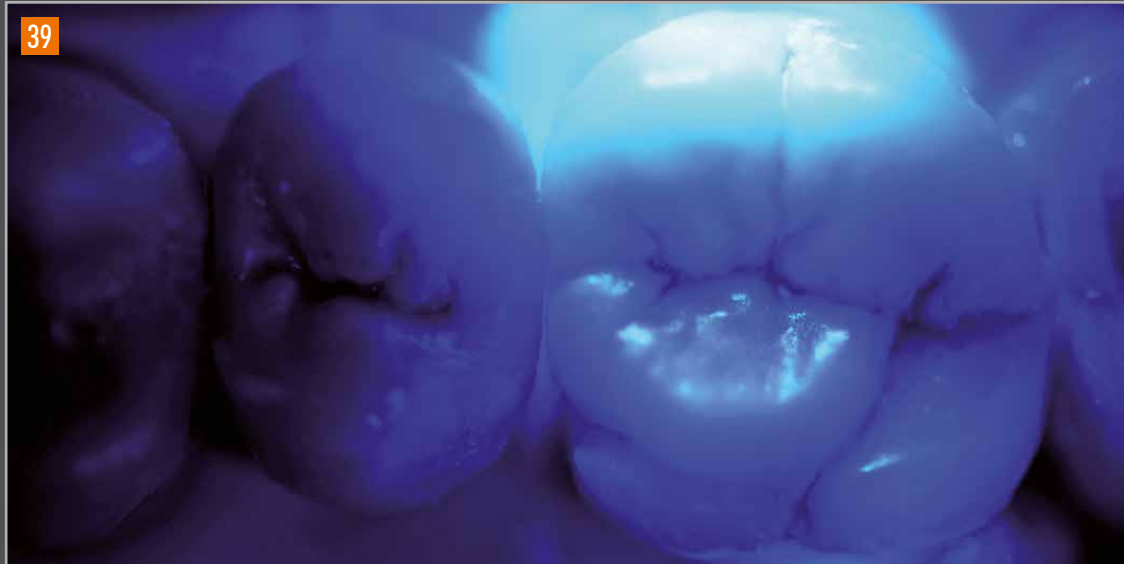Apply dentine-colored adhesive (bonding) material to the central area of the restoration.

38



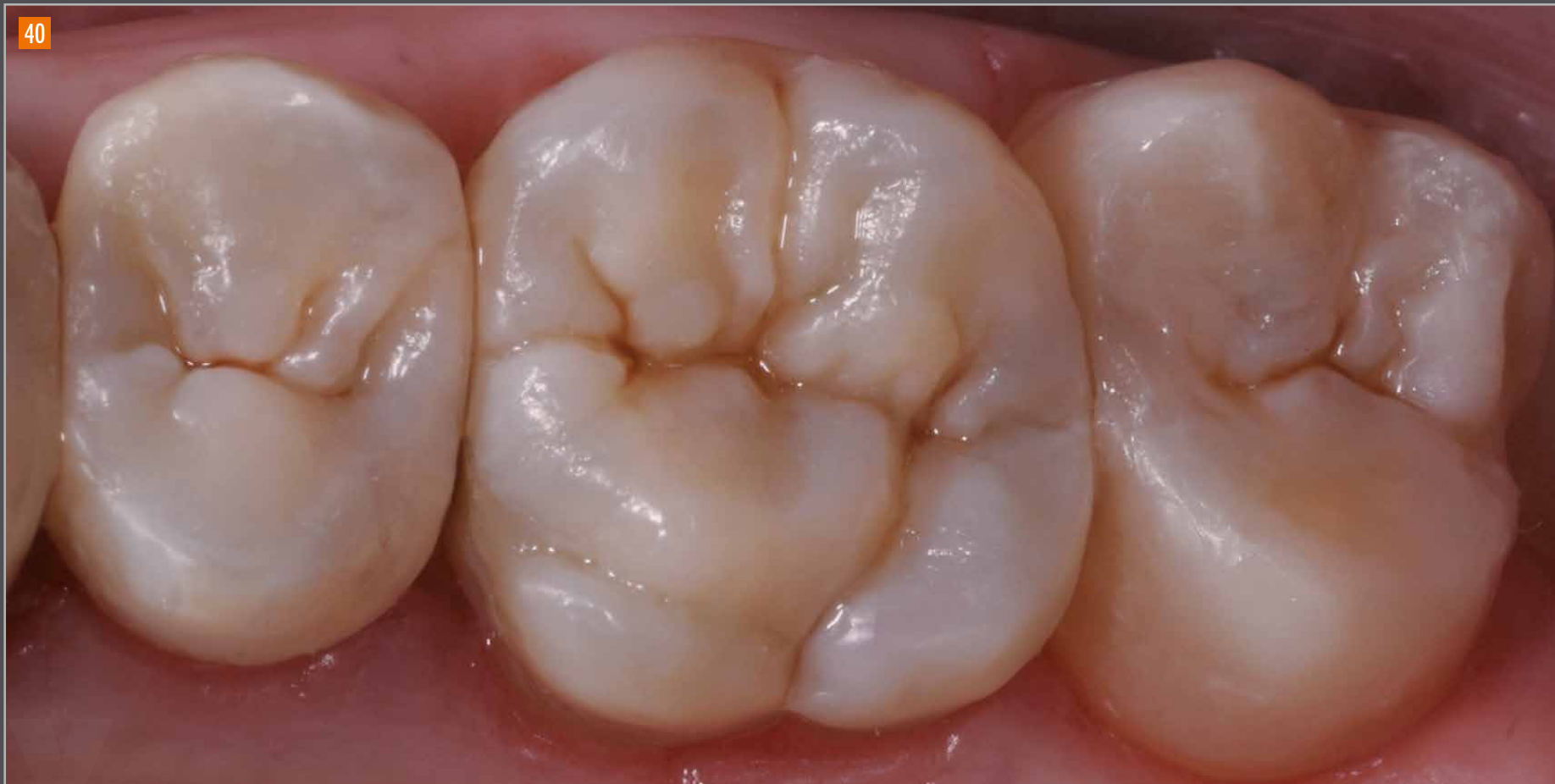Positioning the indirect restorations on the preparations.

Inlay Onlay Overlay



Final polymerization of the bonded indirect restorations.

40

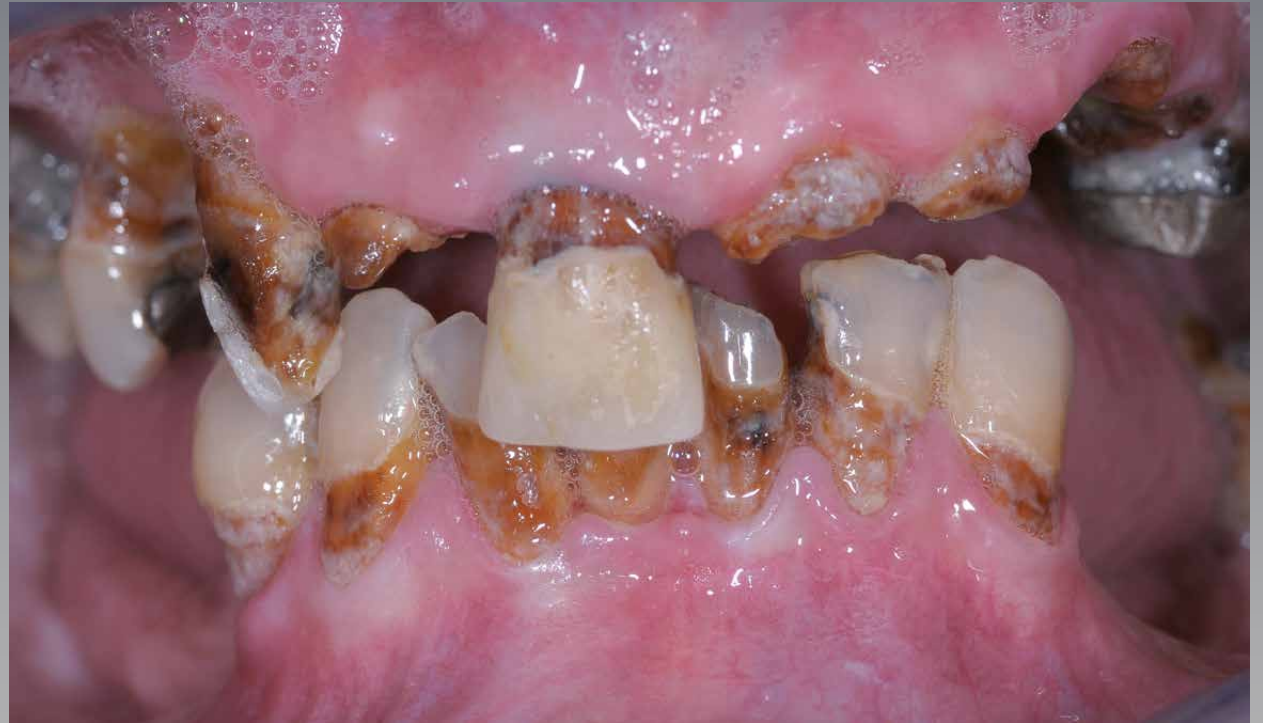

The final result after bonding.

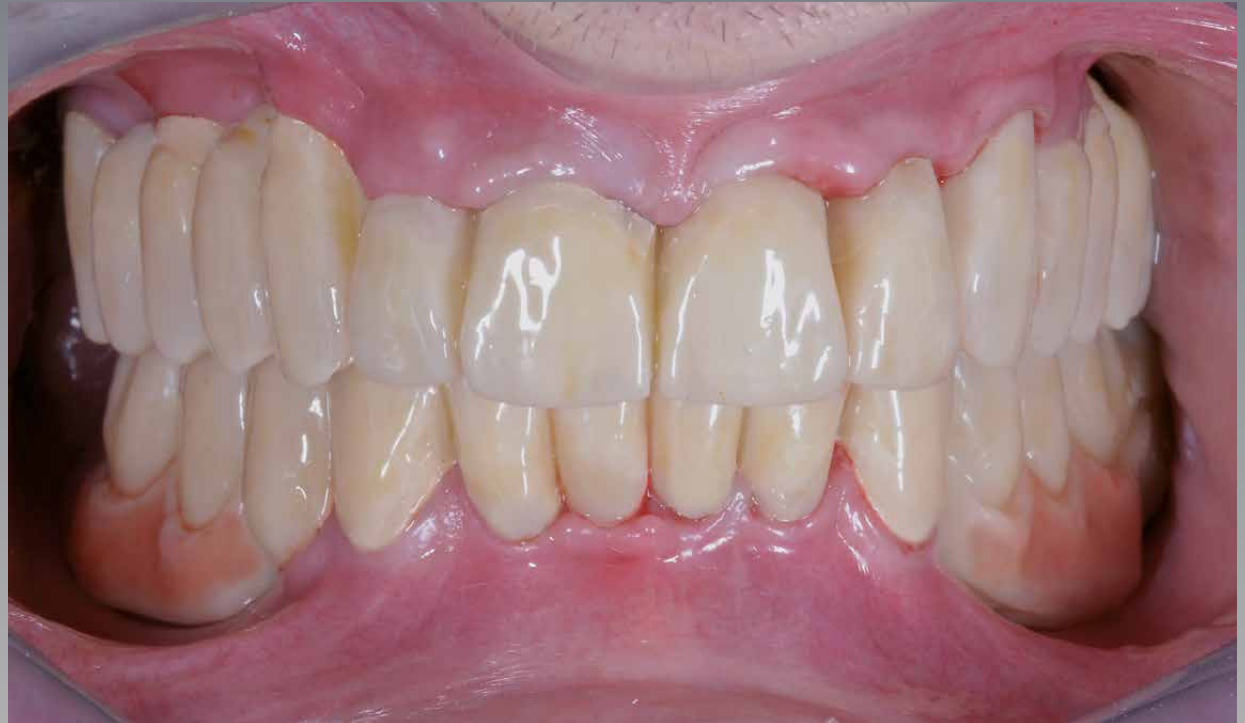bredent^{group}

Complex case with immediate loading

Initial situation



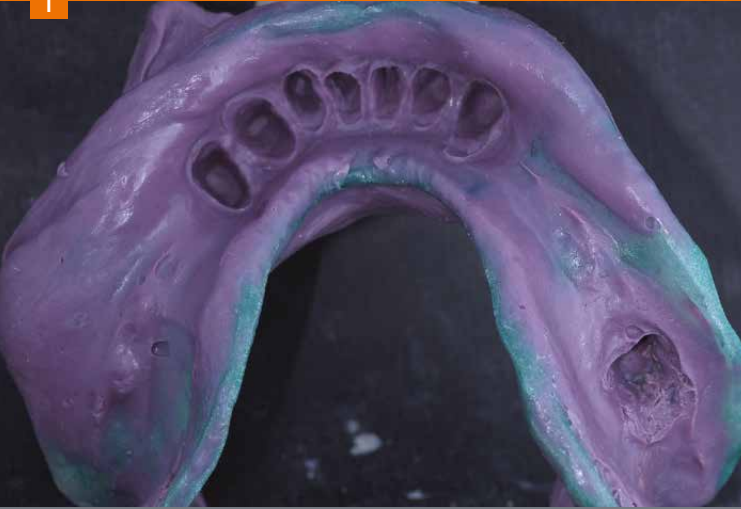
Temporary restoration prior to preparation



A temporary wax-up with guided registration is the basis for determining the temporary restoration.

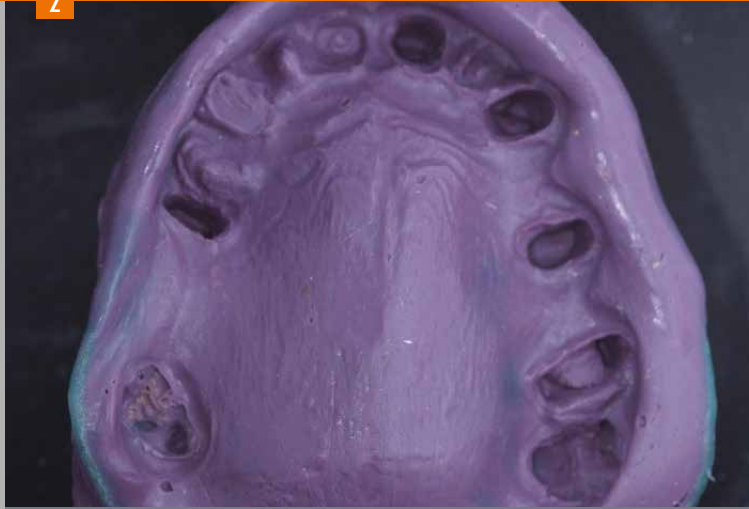Complex case with immediate loading

1



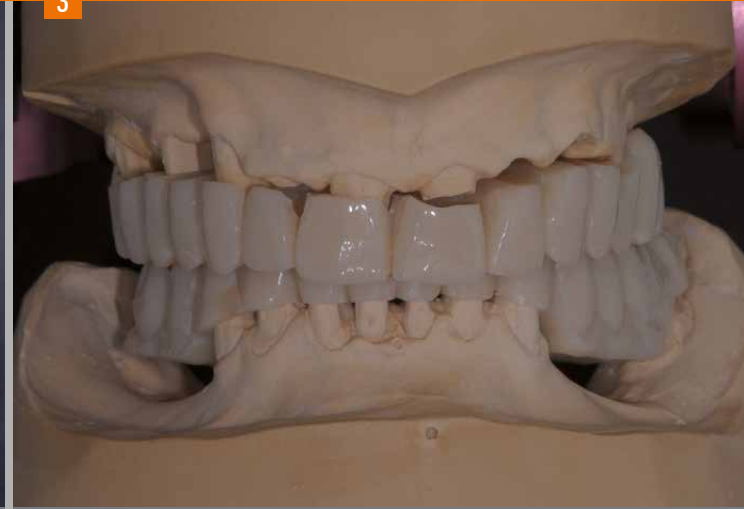Lower impression made of polyether.

2



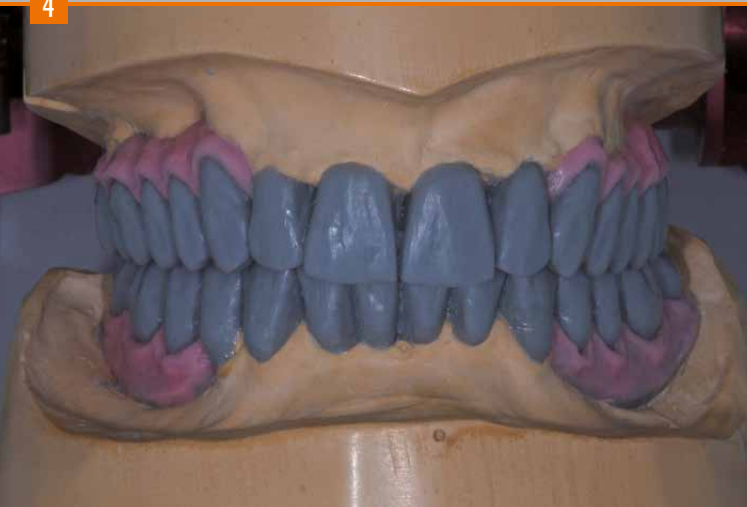Upper impression made of polyether.

3



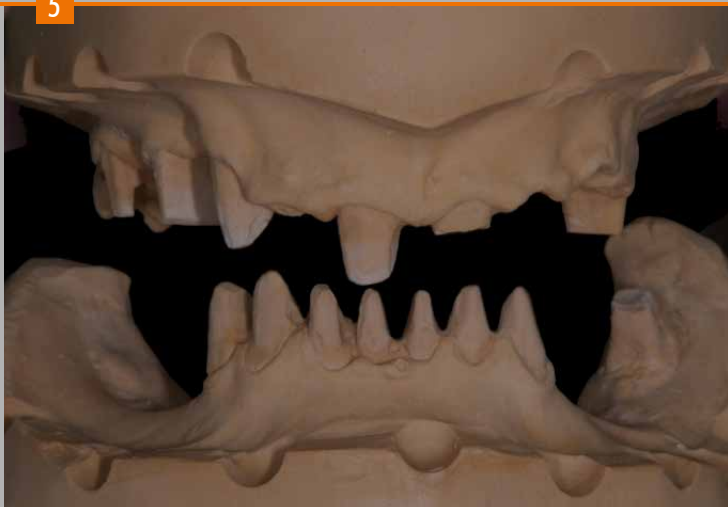
Models are mounted in the articulator in accordance with the bite registration obtained from duplicating the temporary.

4



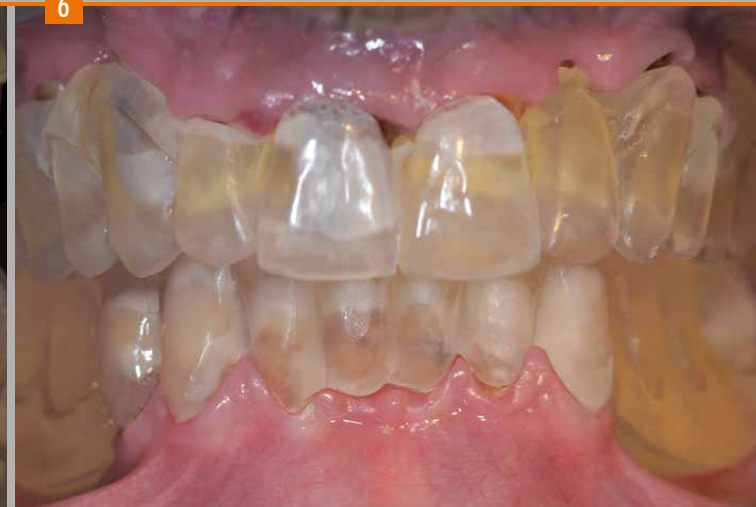Completed diagnostic wax-up.

5



Before preparing the silicone keys of the model, it is necessary to notch the models to obtain the exact position of the keys.

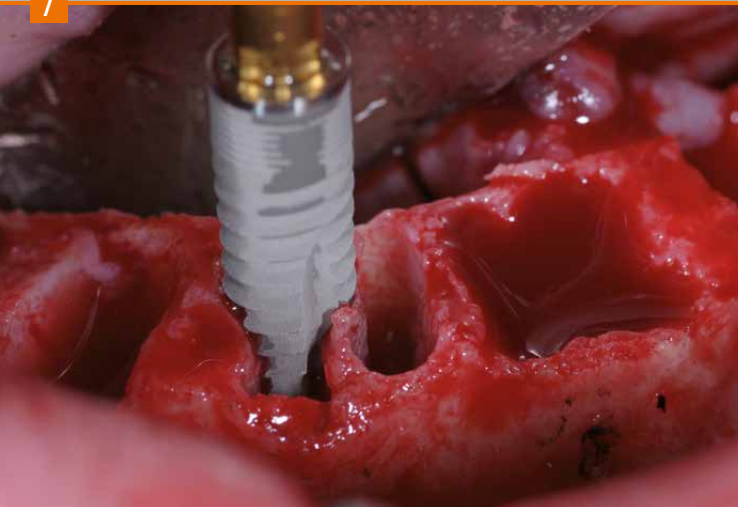
6



Drilling templates with transfer keys. They are used for positioning the implants during surgery and for the transfer of the implant position to the original model.

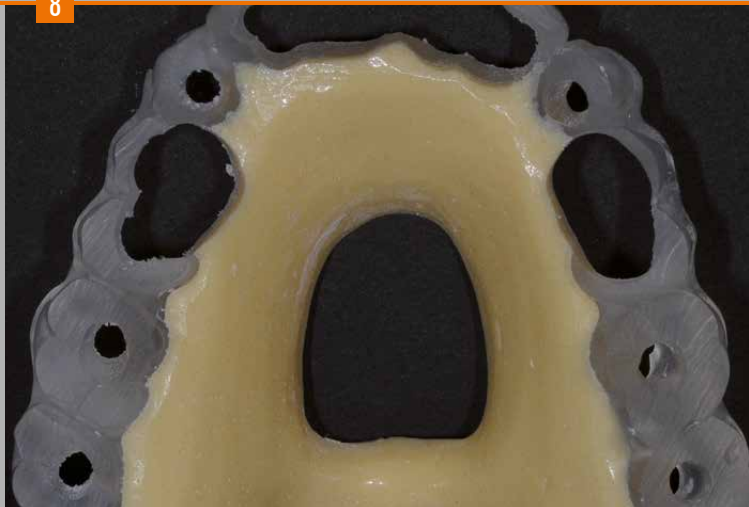
Complex case with immediate loading

7



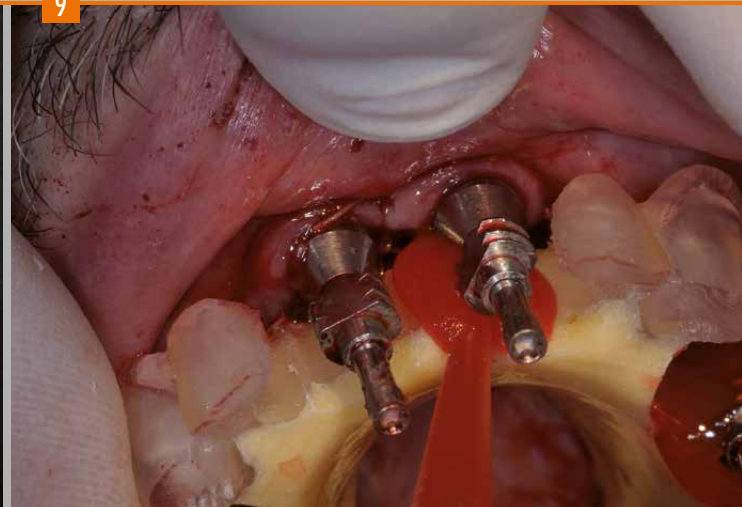
Surgical phase with extraction of the teeth and insertion of the blueSKY implants.

8



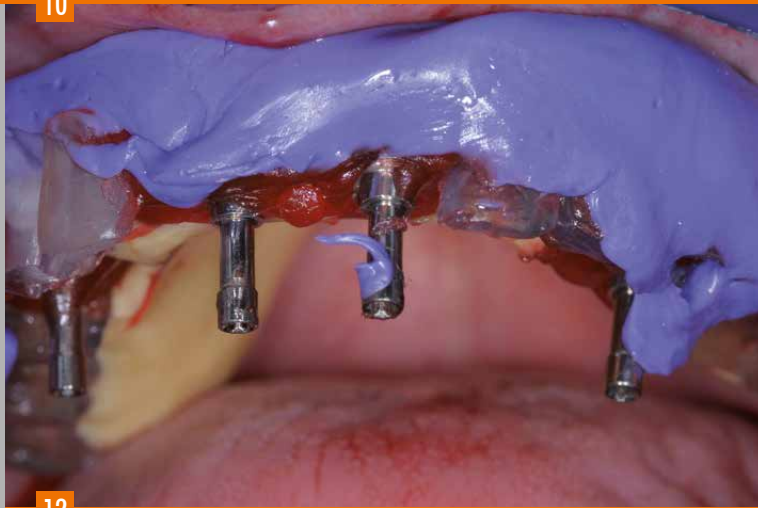
After insertion of the implants, the drilling template is prepared for fixation of the impression abutments and used as a transfer key for subsequent, accurate positioning of the laboratory analogs on the original model.

9



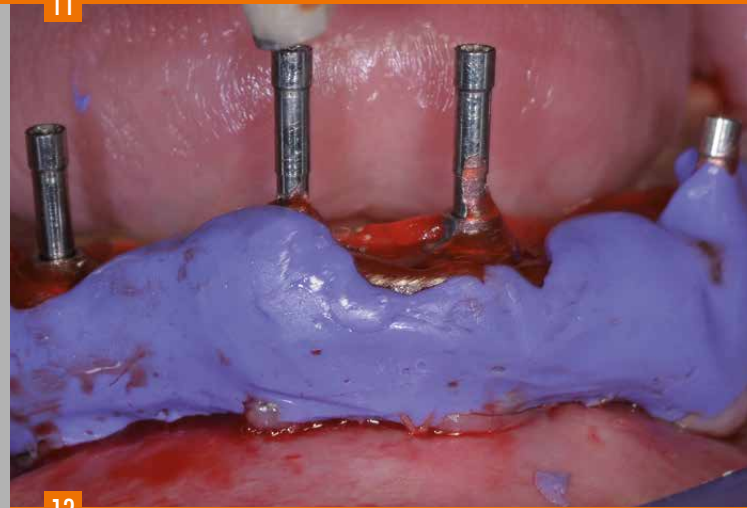
Resin is used for fixation of the impression abutments on the drilling template with transfer key.

10



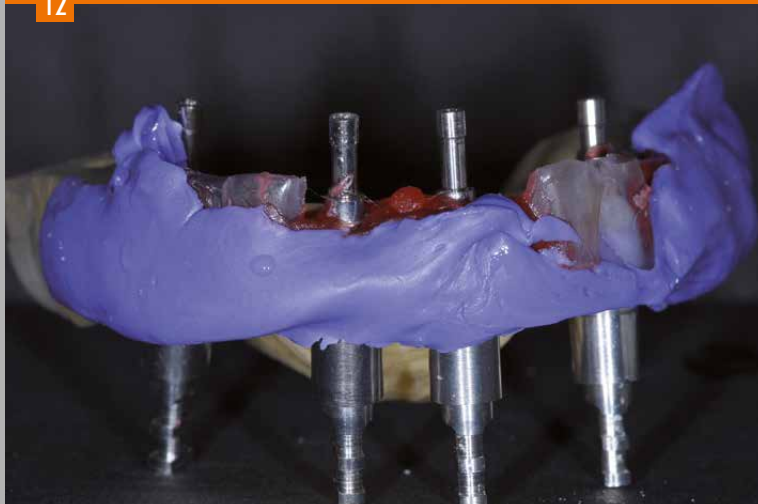
The upper transfer key with the impression abutments fixed with resin.

11



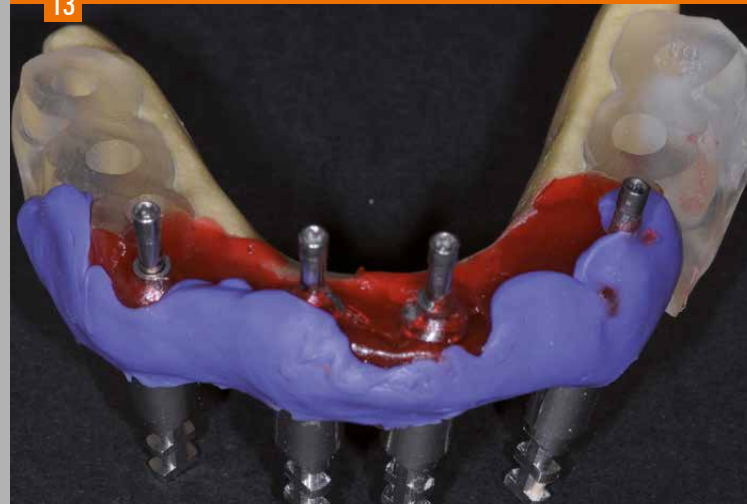The lower transfer key with the impression abutments fixed with resin.

12



The upper transfer key with screwed laboratory analogs.

13



The lower transfer key with screwed laboratory analogs.

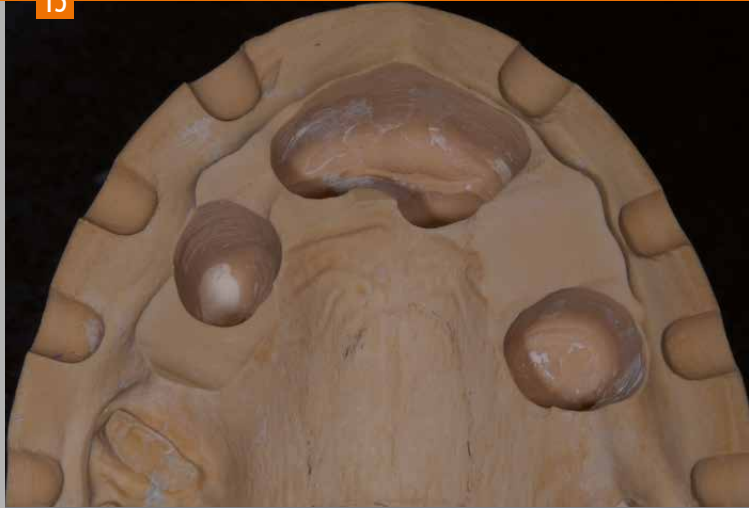Complex case with immediate loading

14



The plaster model is ground with a bur in order to place the laboratory analogs into the exact position (passive fit).

15

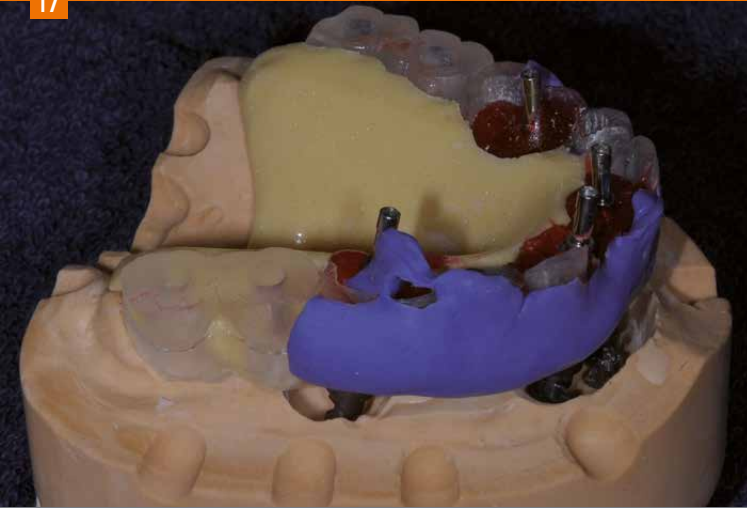


16



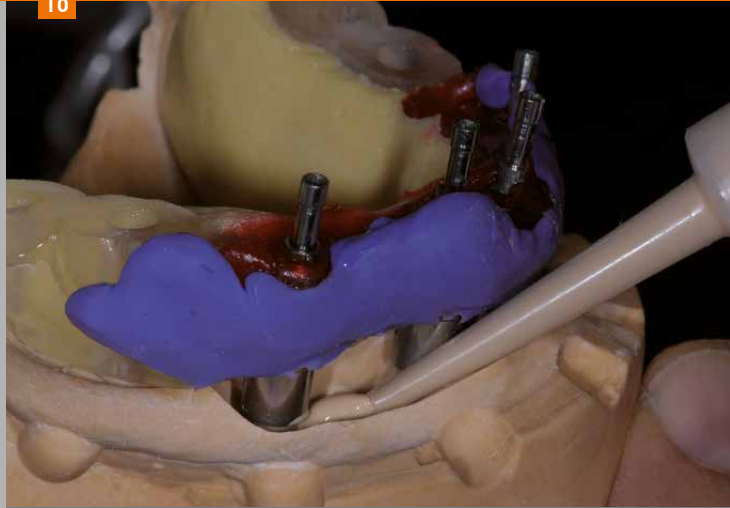
Accurate preparation of the two models for positioning of the drilling templates as transfer keys (with screwed laboratory analogs).

17



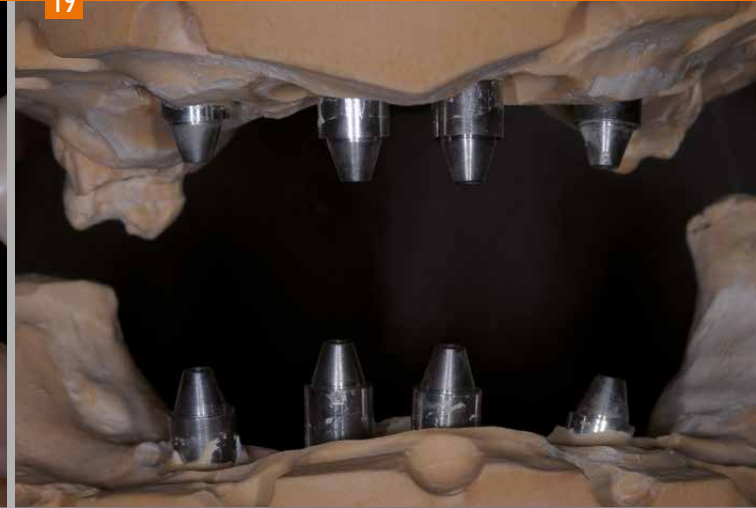The upper transfer key accurately placed on the model.

18



The areas of the previously ground upper and lower plaster models are filled with class IV stone, Thixo-Rock, using a syringe.

19



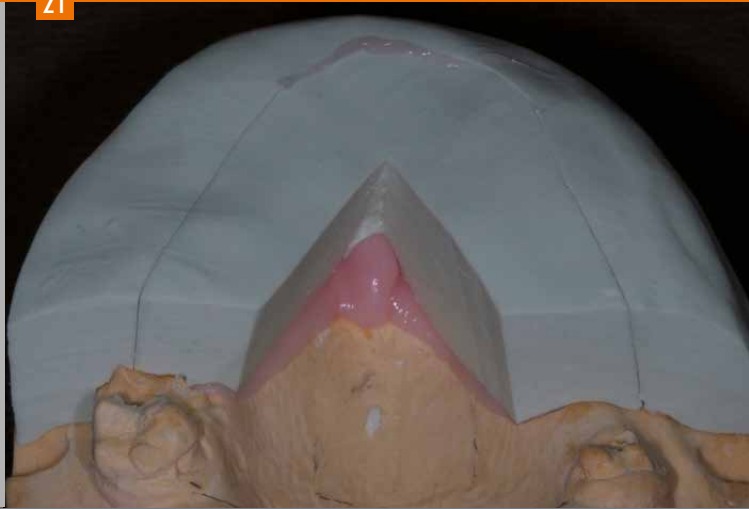
Front view of the two models mounted in the articulator with screwed conical abutments of the SKY fast & fixed system.

Complex case with immediate loading

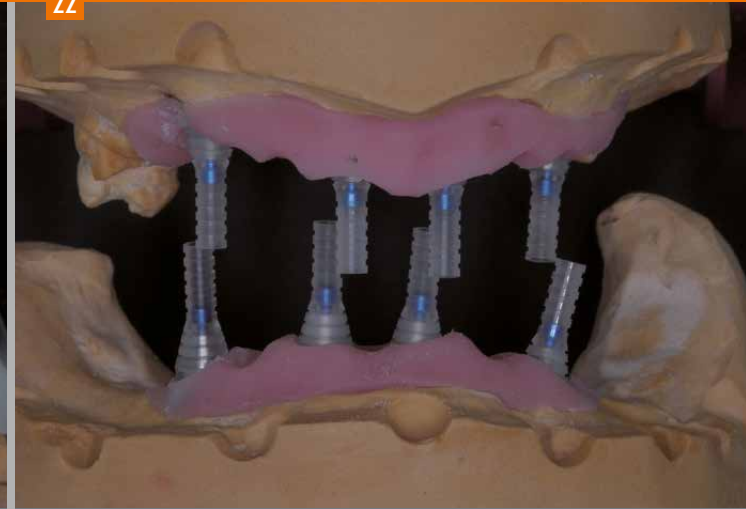
20



21



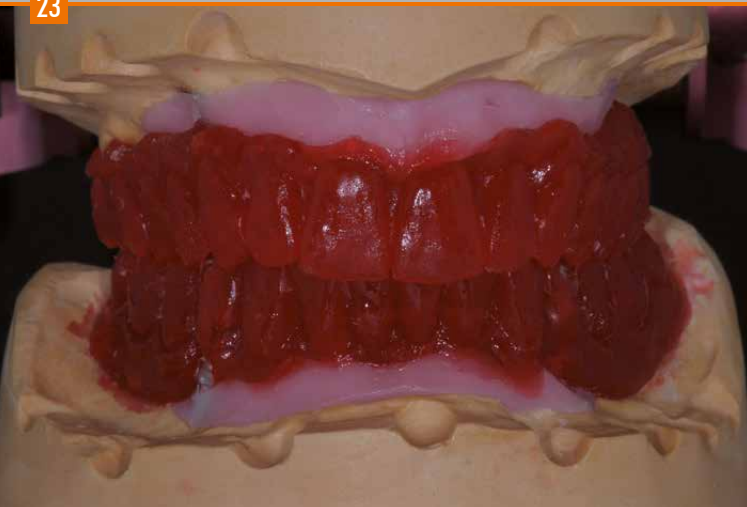22



With a previously prepared key, the soft gingival mask is produced using pink silicone.

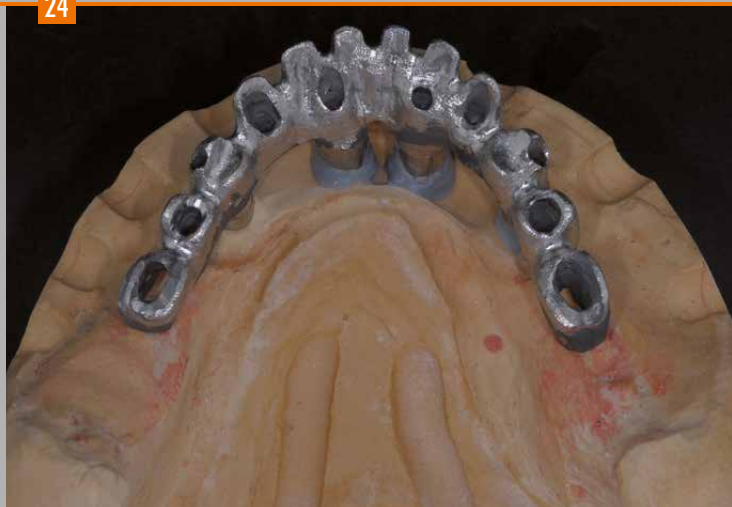Front view of the two models mounted in the articulator with the accurately transferred implant positions and the restoration of the soft tissue from the presurgical phase.

23



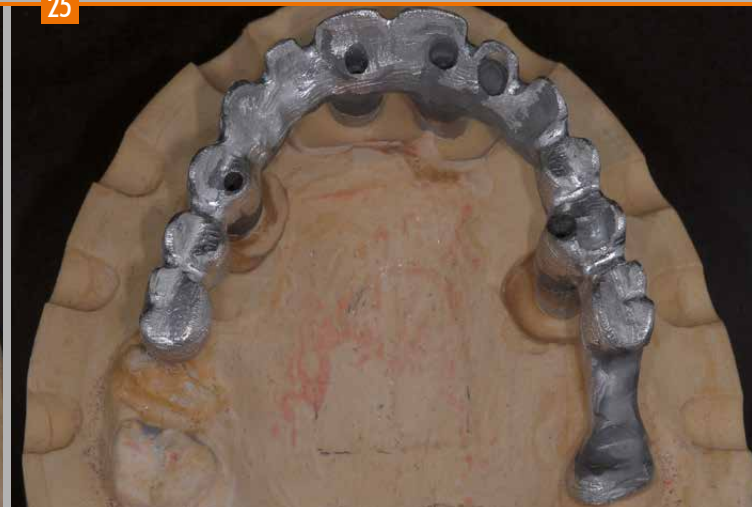The wax-up is duplicated with burn-out Pi-Ku-Plast HP36 resin to obtain two models. While taking the layer thickness into account, the resin model is reduced appropriately. A dimensionally accurate resin framework is obtained for the casting technique.

24



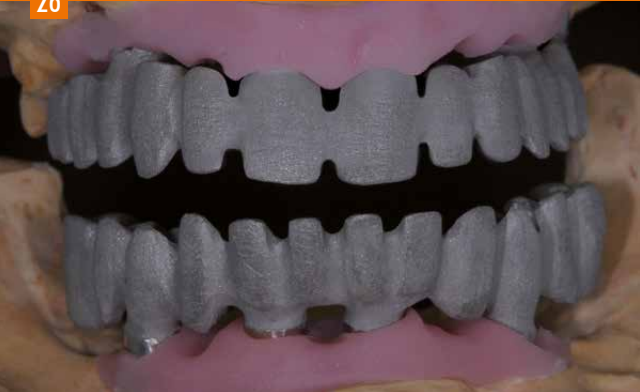The two metal substructures are carefully finished and fitted to the implant abutments.

25

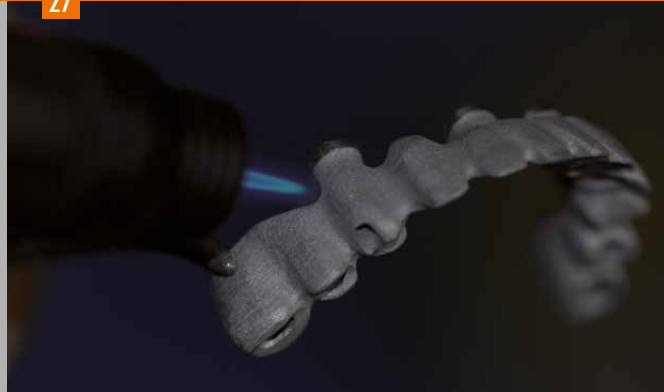

Complex case with immediate loading

26



27



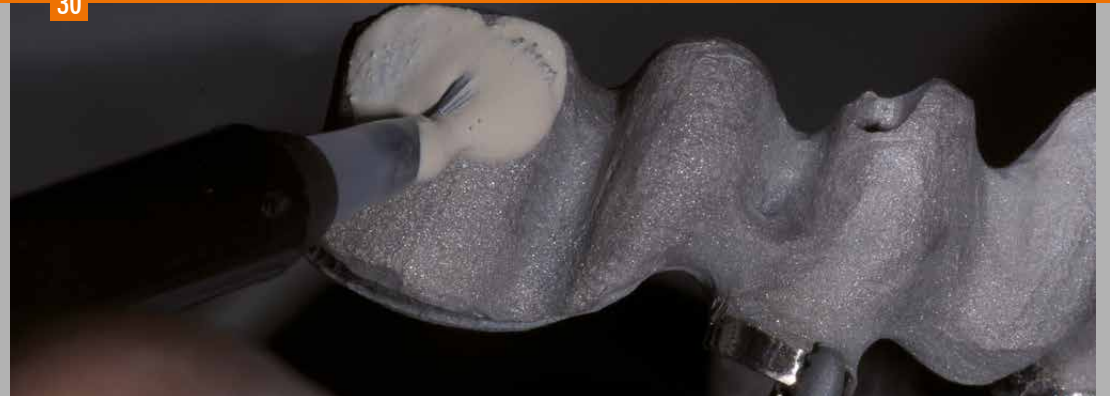28



29



30



The cast and finished substructures are prepared for chemical bonding with Silano-Pen [Fig. 26]. Sandblasting with aluminium oxide ($110\ \mu\text{m}$), then surface treatment with the Silano-Pen flame, which leaves silicate particles on the surface (silica coating) [Fig. 27].

After a few minutes the primer can be applied to the treated surface to activate the ceramic layer (silanization) [Fig. 28 and 29]. combo.lign opaque material can than be applied [Fig. 30].

31



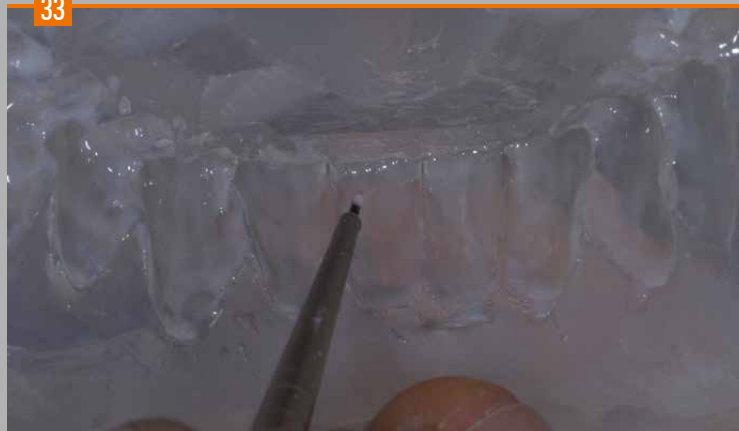Inverse layering of the composite starts in the silicone key of the wax-up. The Bleach dentine material BL3 is applied to the marginal ridges in the posterior region and in the anterior region to accentuate the incisal ridges.
Pre-curing: 2-3 sec.

32



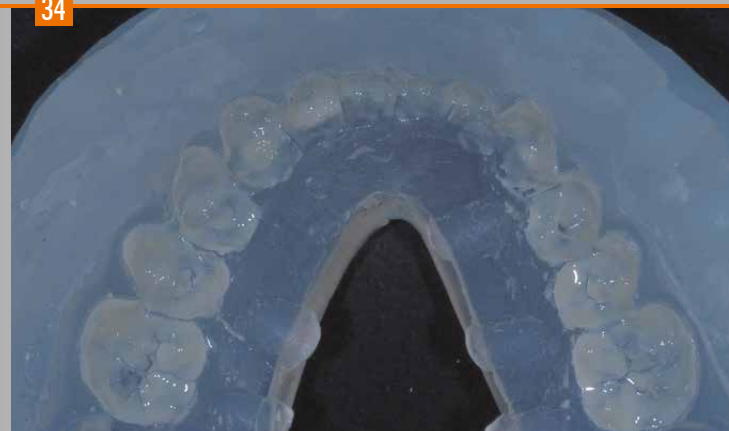E2 incisal material and incisal opal material can then be applied.
Pre-curing: 2-3 sec.

33



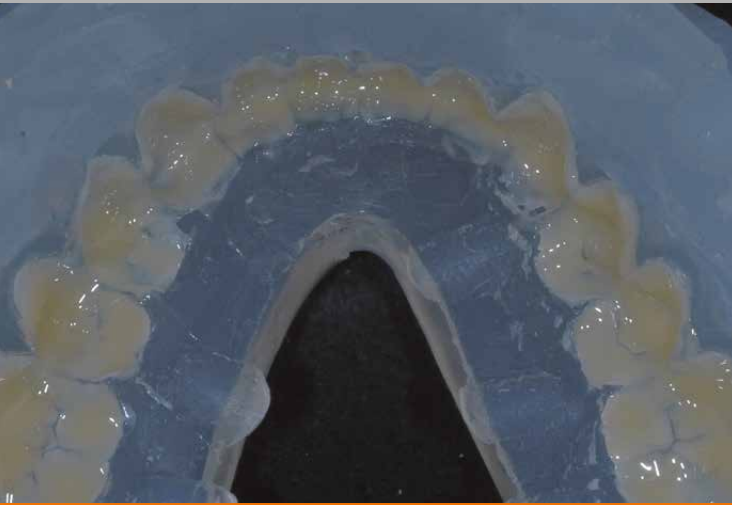Application of the internal stains and effect materials, such as Crack-line, in the anterior region
Pre-curing: 2-3 sec.

34

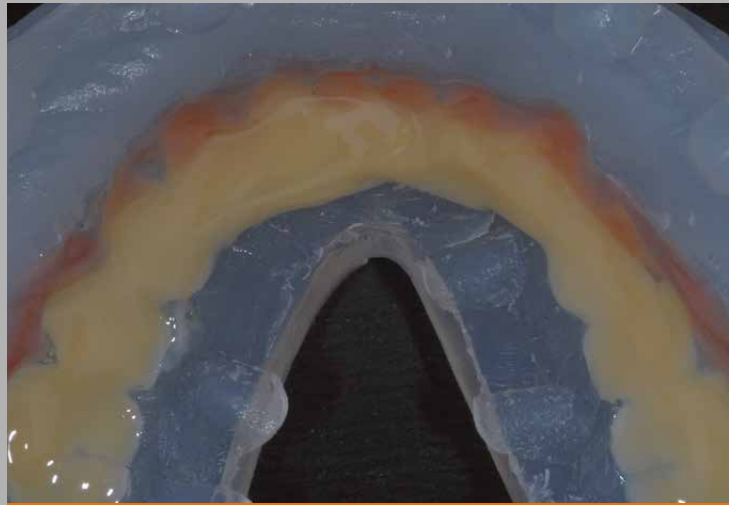


Application of E3 incisal material.
Pre-curing: 2-3 sec.

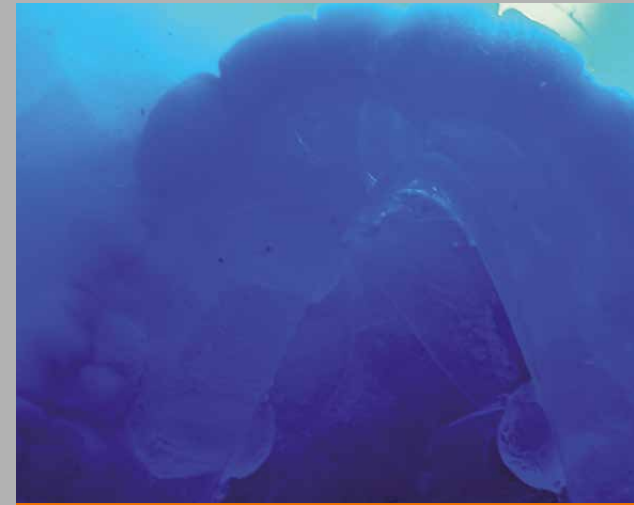Complex case with immediate loading



Application of A2 dentine material
Pre-curing: 2-3 sec.

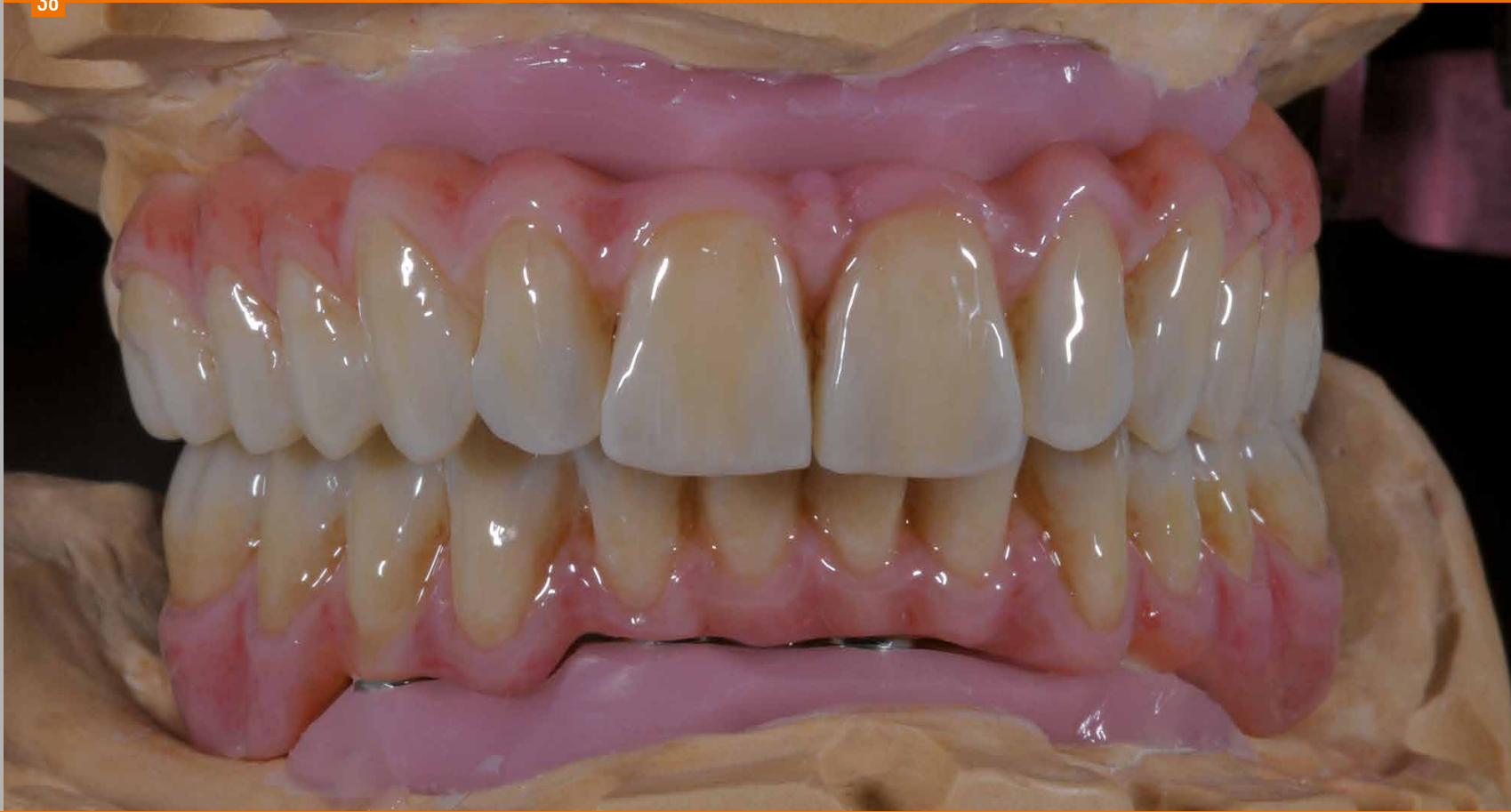

A3 dentine material is applied almost to the top of the key to achieve an enhanced effect of depth and the gingiva is layered with gum materials (rose, pink and light).
Pre-curing: 2-3 sec. After each layer of approx. 1 mm, intermediate curing is carried out in the bre.Lux Power Unit (180 sec.).



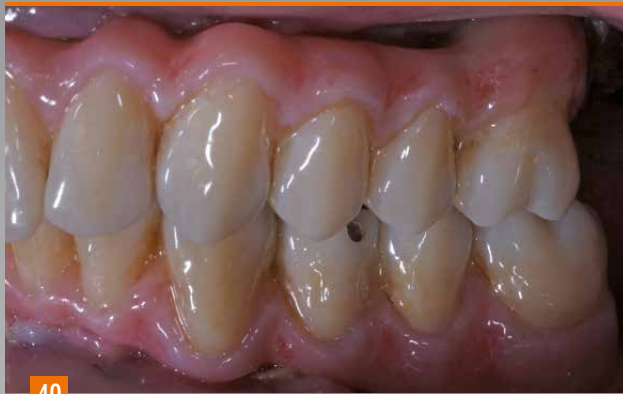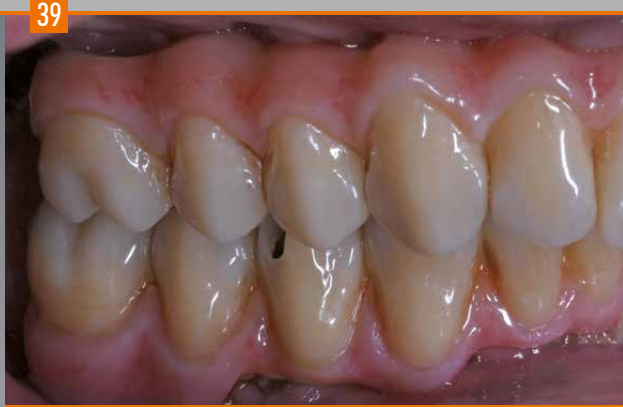Once layering is completed, the key is repositioned on the model and the last curing cycle (360 sec.) is carried out.

38

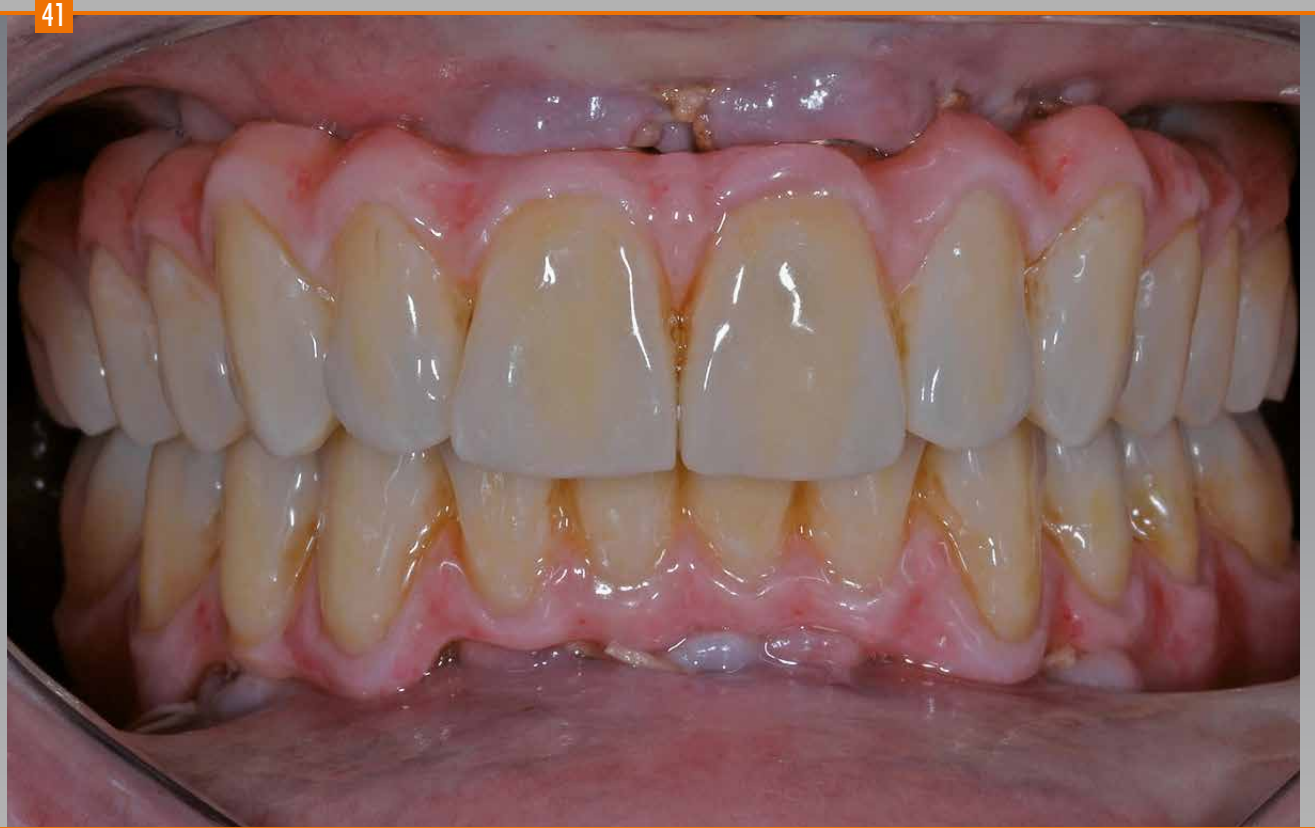

Completed, finished
and polished restora-
tion on the model.

Complex case with immediate loading



Lateral view of the restoration.

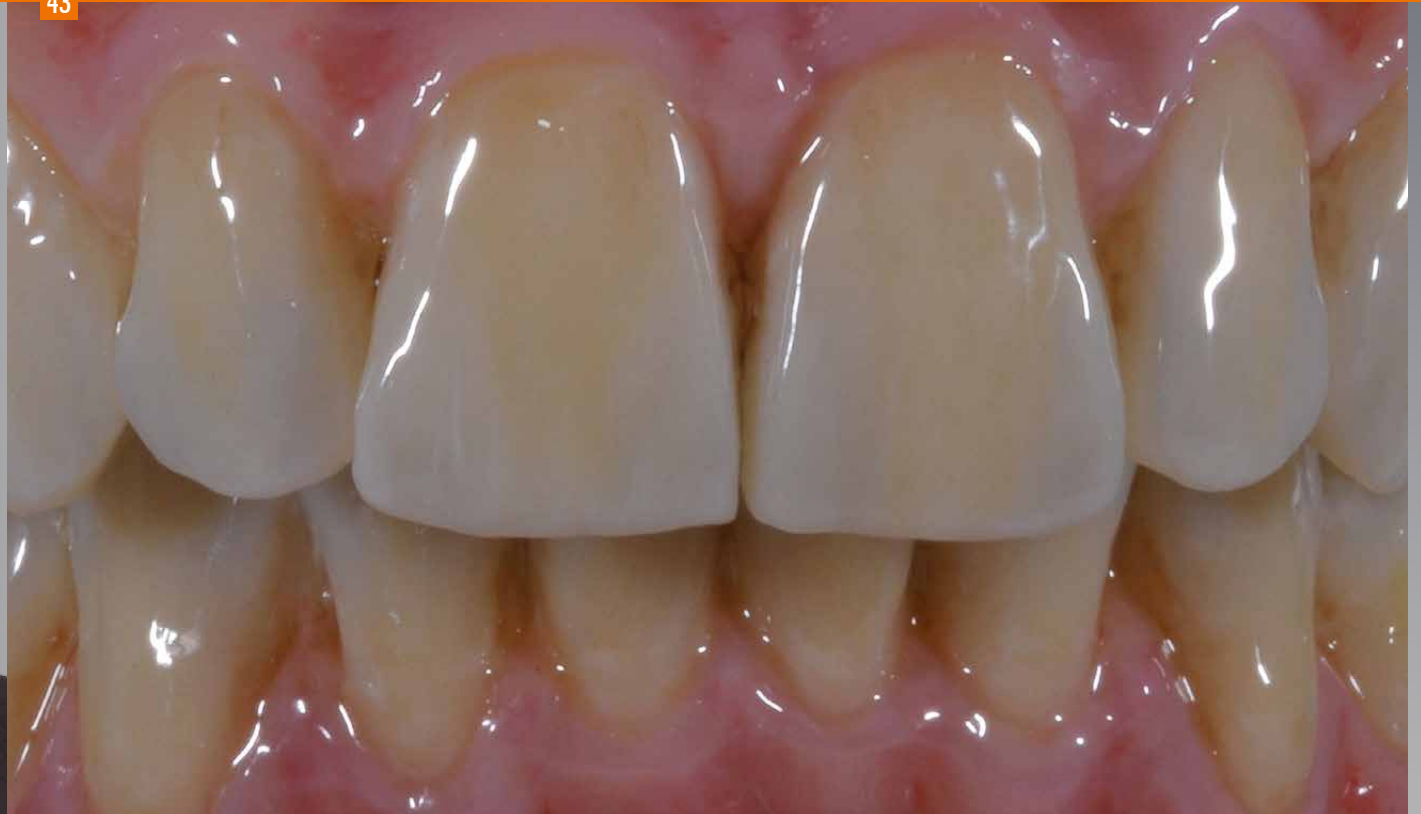

**Front view of the restoration with immediate loading
48 hours after surgery.**

42



43



VINCENZO MUSELLA

The Italian dental technician **Vincenzo Musella** whose interest in dental techniques was aroused by Prof. Mario Martignoni, received his diploma from the renowned Institute Galvani in the province of Reggio Emilia (Italy) and has been running a laboratory in Modena since 1988. During his career he enhanced his skills and knowledge in numerous training events, which brought him together with Giuseppe Zuppari (dental technician) in 1996.

Today, they both share a long-standing friendship and closely cooperate in the development of various possibilities with ceramic restorations. Furthermore he cooperates with his dear friend Dr. Dario Castellani and in 1999 he initiated (together with Giuseppe Zuppari) a course program for ceramic restoration especially tailored towards the needs and requirements of young people.

V i n c e n z o



In the following years he worked with Prof. Jeffrey Okeson, the head of the Center of Orofacial Pain at the University of Kentucky until 2002. He also actively cooperated with Prof. Angelo Putignano in the development of new materials and completion of patient cases. He is currently studying dentistry and dental prosthetics at Università Politecnica delle Marche in Ancona (Italy).

M u s e l l a

Musella

Thanks to Dr. Dario Castellani, Dr. Luca Cantoni, Dr. Alessandro Agnini, Dr. Cinzia Barbieri and Prof. Pierangelo Oliveri for their valuable clinical support.

Special thanks go to our dear friend Pier Paolo Goldoni for his continued efforts and support of our work.

Scheme of inverse layering

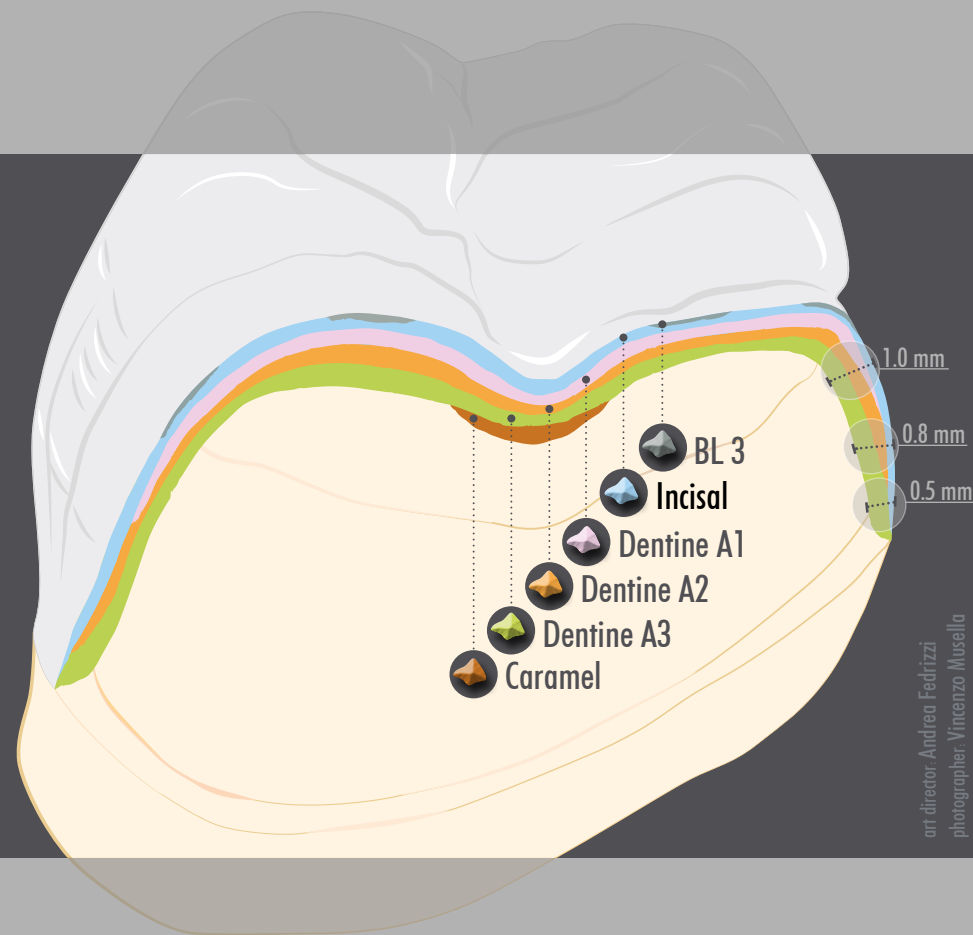
crea.lign layering materials are perfectly suitable for minimally invasive layering and veneering technique in cases of limited available space. The dentine shades feature somewhat higher chroma than dental composites for the veneer technique and the incisal materials are a bit lighter and highly opalescent.

It is favourable to have different levels of chroma which would mean that the selected tooth shade of the classic A-D shade guide would be layered as secondary dentine, e.g. A3 and then equal quantities of A2 and A1 dentine materials are applied over the top, if the layer thickness is more than 0.5 mm. The layer thickness of these primary dentine materials, however, should always be lower than

the thickness of the secondary dentine material. Significant color depth and contrast can be achieved, especially in the veneer technique, so even devitalized teeth can be covered in a minimally invasive manner.

As shown in the case described, the incisal material selected in the posterior region is always one shade lighter than in the anterior region (for A3: E2 instead of E3).

The opal enamel material is the only non-fluorescent material. If enamel materials need to appear more transparent, it is recommended to mix the respective enamel material with crea.lign Modelling Liquid in a ratio of max. 30%.



art director: Andrea Fedrizzi
photographer: Vincenzo Musella

bredent

GmbH & Co. KG · Weissenhorner Str. 2 · 89250 Senden · Germany · T: (+49) 0 73 09 / 8 72-4 41 · F: (+49) 0 73 09 / 8 72-4 44
www.bredent.com · @: info@bredent.com

000482GB-20120601



Mistake and subject to change reserved

visio.lign
crea.lign

